

# **ECOCARDIOGRAFIA 2015** **XVII Congresso Nazionale SIEC**

**Hotel Royal Continental**

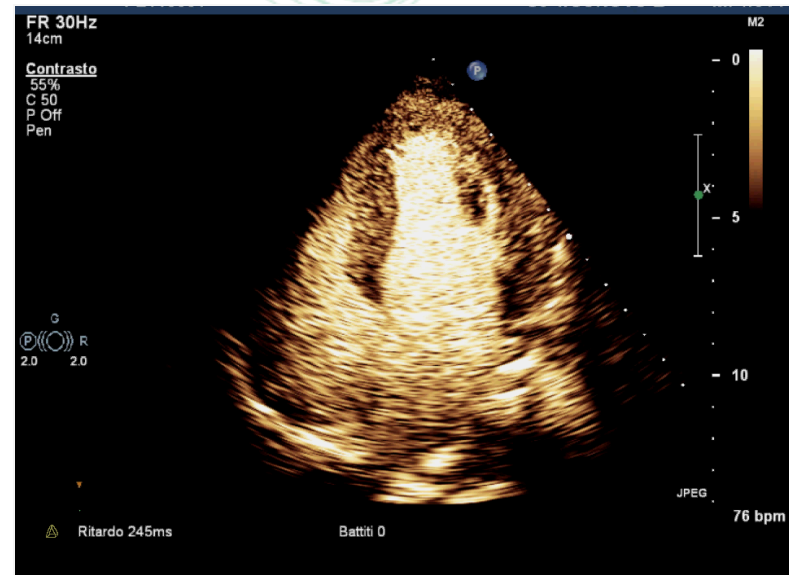
**Napoli, 16-18 Aprile 2015**

**VALORE INCREMENTALE  
DELL' ECOCONTRASTO:  
DALL' OPACIZZAZIONE ALLA  
PERFUSIONE  
DIAGNOSI DI TROMBI E MASSE**

**Agata Barchitta**  
Medicina d' Urgenza  
Ospedale S. Antonio  
Padova

# CEUS - Contrast Enhanced Ultrasound

- La **CEUS** è una metodica di imaging ecografico in grado di visualizzare **in tempo reale il macro e microcircolo**. La metodica ha un eccellente profilo di tollerabilità e sicurezza ovvero nessuna radiazione, nessuna nefrotossicità, minimamente invasiva.
- I mezzi di contrasto US sono iniettati IV e sono confinati nello spazio vascolare.
- Sono dei blood pool agents.
- Le Microbolle agiscono come i Globuli Rossi



# Event Rates for Commonly Performed Cardiovascular Procedures

Procedure	Event Rate	Event
Coronary Angiography	1:1000	Death
Exercise Treadmill Testing	1:2500	MI or Death
SPECT Exam or Radionuclide Ventriculography	1:1000 to 1:10,000	Fatal Malignancy
Contrast Echocardiography	1:500,000	Death

# CEUS: Perché

- ❑ I MdC in ecocardiografia sono registrati e utilizzati per la valutazione della funzione del Ventricolo Sx quando la visualizzazione del bordo endocardico è limitata e/o insufficiente
- ❑ Questa valutazione corrisponde a circa il la metà delle richieste e, di queste, in circa il 5- 15% dei pazienti si ha un'insufficiente visualizzazione del bordo endocardico
- ❑ Questa percentuale sale fino al 50% nell'ecostress per l'induzione di ischemia

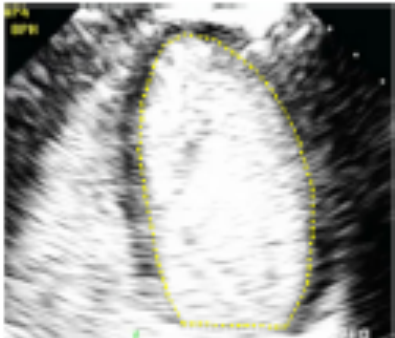
# CEUS: Linee Guida Internazionali

- **Contrast echocardiography**: evidence-based recommendations by European Association of Echocardiography (EAE)  
Senior et al, Eur J Echocardiography 10, 2009, 194-212
- EAE - **Stress echocardiography** expert consensus statement  
Sicari et al, Eur J Echocardiography 9, 2008, 415-437
- EAE - Recommendations for echocardiography use in the diagnosis and management of **cardiac sources of embolism**  
Pepi et al, Eur J Echocardiography 11, 2010, 461-476
- EAE-ASE - Recommendations for **chamber quantification**  
Lang et al, Eur J Echocardiography 7, 2006, 79-108
- EAE-ASE - Recommendations for image acquisition and display using **three-dimensional echocardiography**  
Lang et al, Eur. Heart Journal – Card. Imaging 13, 2012 1–46

# Recommendations for Cardiac Chamber Quantification by Echocardiography in Adults: An Update from the American Society of Echocardiography and the European Association of Cardiovascular Imaging

Roberto M. Lang, MD, FASE, FESC, Luigi P. Badano, MD, PhD, FESC, Victor Mor-Avi, PhD, FASE, Jonathan Afilalo, MD, MSc, Anderson Armstrong, MD, MSc, Laura Ernande, MD, PhD, Frank A. Flachskampf, MD, FESC, Elyse Foster, MD, FASE, Steven A. Goldstein, MD, Tatiana Kuznetsova, MD, PhD, Patrizio Lancellotti, MD, PhD, FESC, Denisa Muraru, MD, PhD, Michael H. Picard, MD, FASE, Ernst R. Rietzschel, MD, PhD, Lawrence Rudski, MD, FASE, Kirk T. Spencer, MD, FASE, Wendy Tsang, MD, and Jens-Uwe Voigt, MD, PhD, FESC, *Chicago, Illinois; Padua, Italy; Montreal, Quebec and Toronto, Ontario, Canada; Baltimore, Maryland; Créteil, France; Uppsala, Sweden; San Francisco, California; Washington, District of Columbia; Leuven, Liège, and Ghent, Belgium; Boston, Massachusetts*

**Table 1** (Continued)

Parameter and method	Technique	Advantages	Limitations
	Endocardial border enhancement 	<ul style="list-style-type: none"><li>• Helpful in patients with suboptimal acoustic window</li><li>• Provides volumes that are closer to those measured with cardiac magnetic resonance</li></ul>	<ul style="list-style-type: none"><li>• Same limitations as the above non-contrast 2D techniques</li><li>• Acoustic shadowing in LV basal segments with excess contrast</li></ul>

# Principali applicazioni nel Cuore

## Cuore

### Identificazione CAD

- LVO / EBD a riposo o durante stress (esercizio o farmacologico), quando due o più segmenti di bordo endocardico non sono visualizzabili
- Possibile la visualizzazione della perfusione miocardica (MCE) nello stesso esame (OFF LABEL)

### Valutazione scompenso cardiaco

- Valutazione volumi ventricolare sinistro e EF per:
  - Impianto defibrillatori
  - Monitoraggio cardiotossicità chemioterapie antiblastiche
- Stratificazione prognostica

### Anomalie strutturali pareti VS

- Cardiomiopatia ipertorfica apicale
- Non-compattazione VS
- Pseudo aneurisma del VS

### Identificazione masse intracavitarie

- Trombi apicali
- Tumori intracardiaci

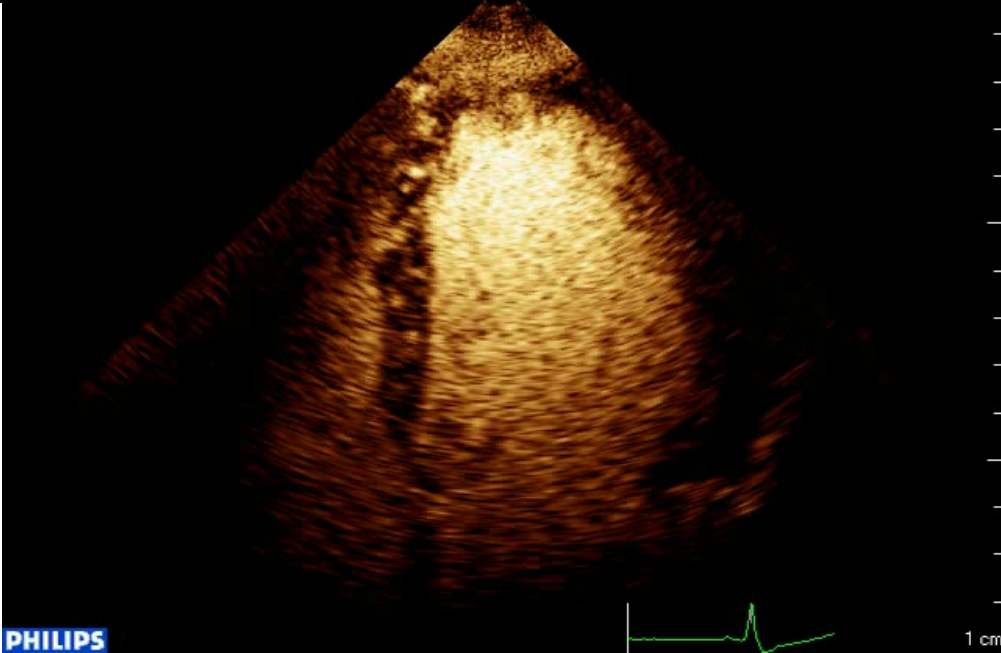
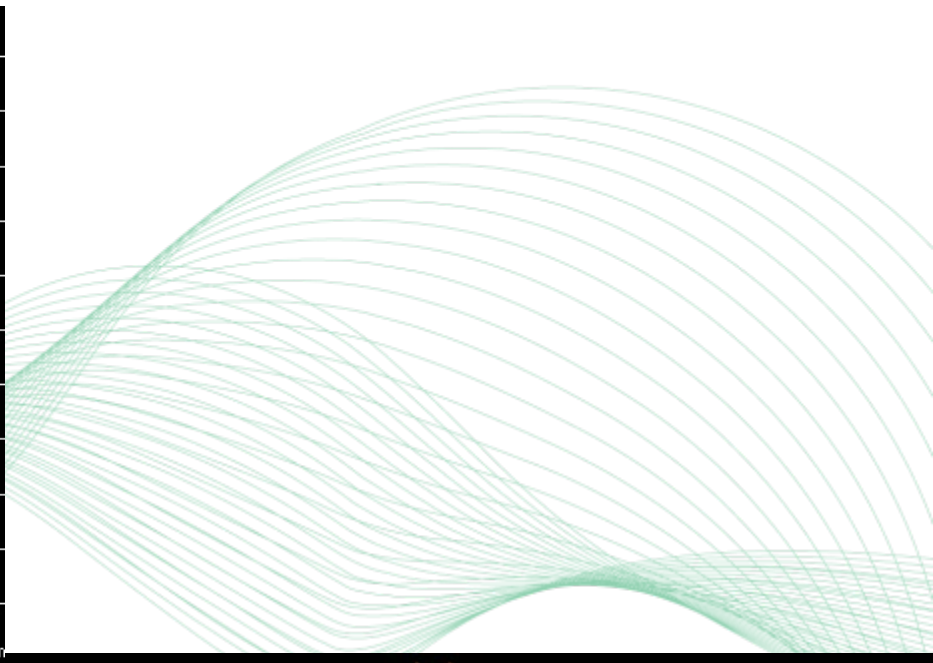
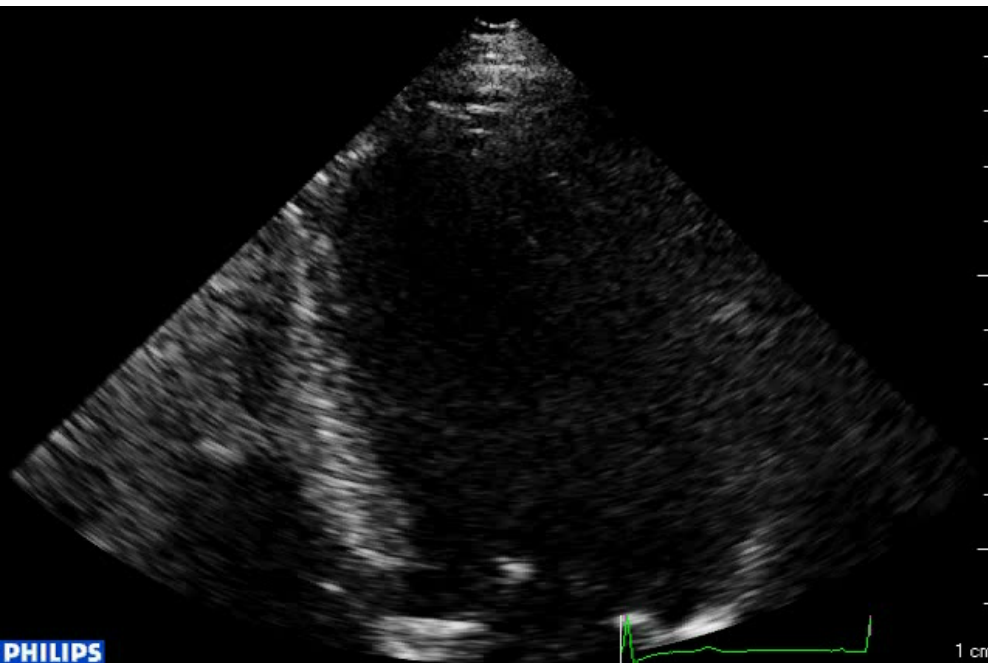

## **Analysis of Left Ventricular Volumes and Function: A Multicenter Comparison of Cardiac Magnetic Resonance Imaging, Cine Ventriculography, and Unenhanced and Contrast-Enhanced Two-Dimensional and Three-Dimensional Echocardiography**

**Results:** LV end-systolic and end-diastolic volumes were underestimated by 2D and 3D unenhanced echocardiography compared with cardiac magnetic resonance. Contrast enhancement resulted in similar significant increases in LV volumes on 2D and 3D echocardiography. The mean percentage of interreader variability for LV EF was reduced from 14.3% (95% confidence interval [CI], 11.7%–16.8%) for unenhanced 2D echocardiography and 14.3% (95% CI, 9.7%–18.9%) for unenhanced 3D echocardiography to 8.0% (95% CI, 6.3%–9.7%;  $P < .001$ ) for contrast-enhanced 2D echocardiography and 7.4% (95% CI, 5.7%–9.1%;  $P < .01$ ) for contrast-enhanced 3D echocardiography and thus to a similar level as for cardiac magnetic resonance (7.9%; 95% CI, 5.4%–10.5%). A similar effect was observed for interreader variability for LV volumes.

**Conclusions:** Contrast administration on 3D echocardiography results in improved determination of LV volumes and reduced interreader variability. The use of 3D echocardiography requires contrast application as much as 2D echocardiography to reduce interreader variability for volumes and EF.

# RIMODELLAMENTO VENTRICOLARE: 2D LVO



PHILIPS

PHILIPS

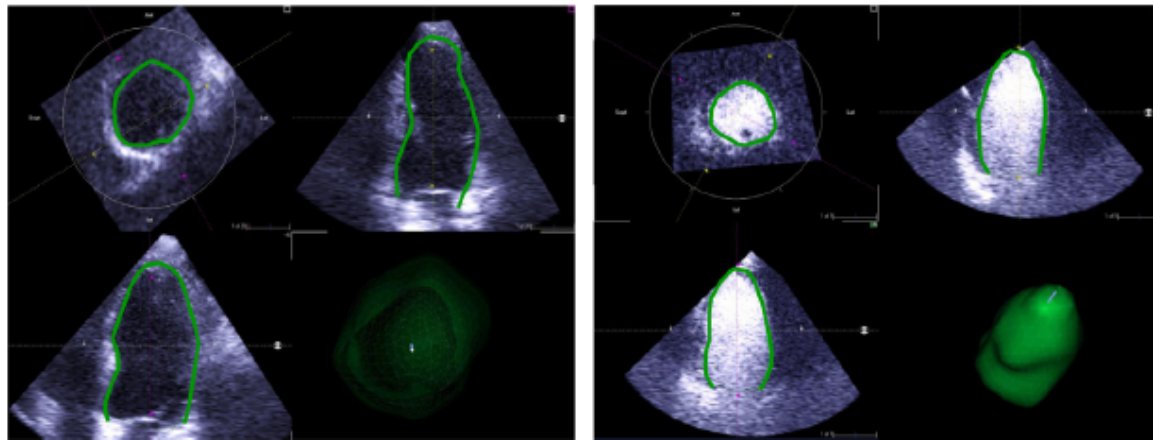
1 cm

# RIMODELLAMENTO VENTRICOLARE: 3D LVO



Journal of the American Society of Echocardiography  
Volume 27 Number 3

Hoffmann et al 295

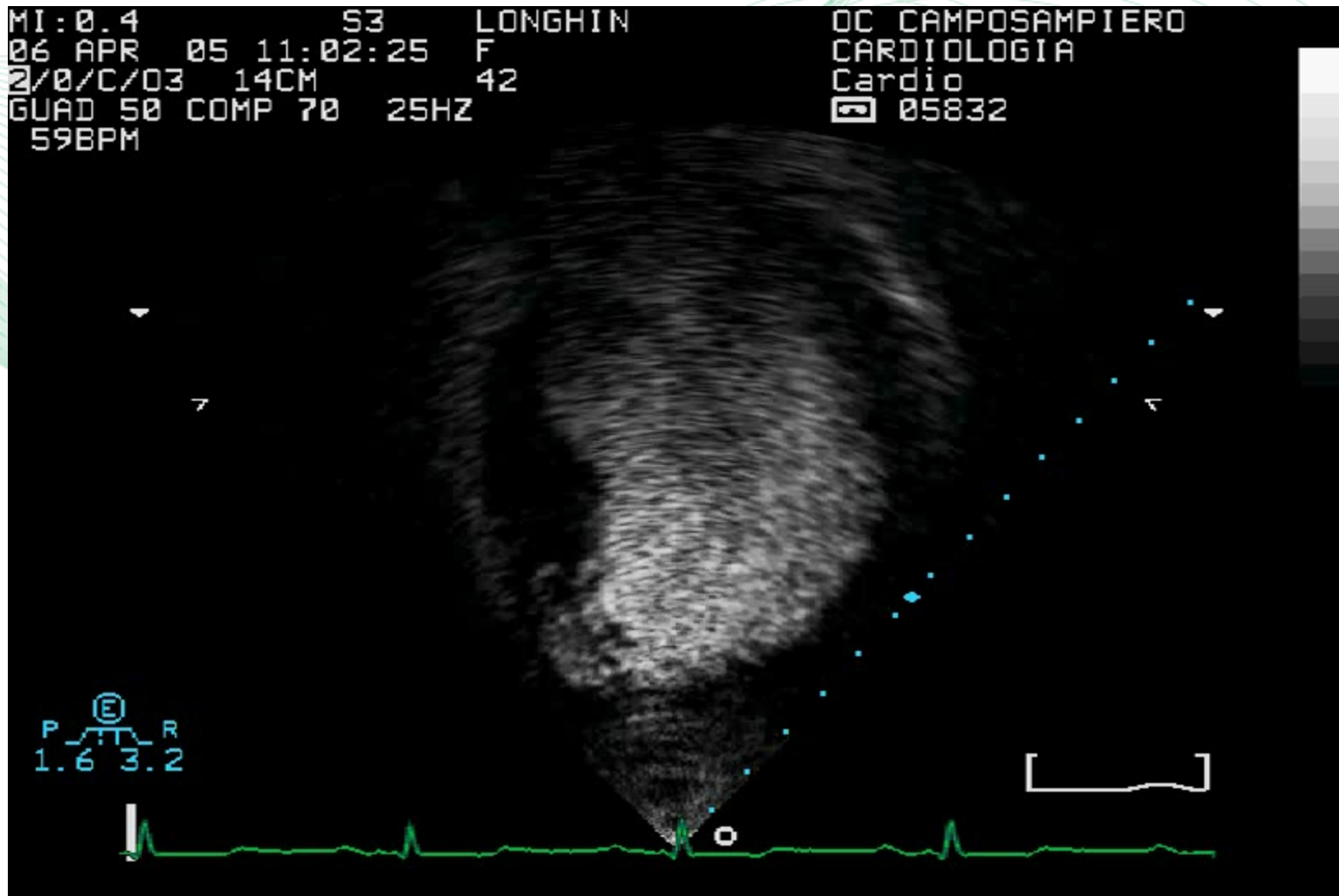


**Figure 1** Apical transthoracic 3D echocardiography display of the left ventricle obtained without (*left*) and with (*right*) administration of contrast agent using contrast-specific low-mechanical index imaging techniques. The *green line* indicates the endocardial tracking.

# Usefulness of Contrast Agents in the Diagnosis of Left Ventricular Pseudoaneurysm after Acute Myocardial Infarction

R. Moreno, J. L. Zamorano, C. Almería, J. L. Rodrigo, A. Villate, V. Serra,  
L. Alvarez, A. Aubele and L. Sánchez-Harquindev

*Eur J Echocardiography* (2002) 3, 111–116



# CEUS : Rimodellamento e Cardiopatia ipertensiva

## Myocardial contrast Echocardiography in the Evaluation of Hypertensive Heart Disease

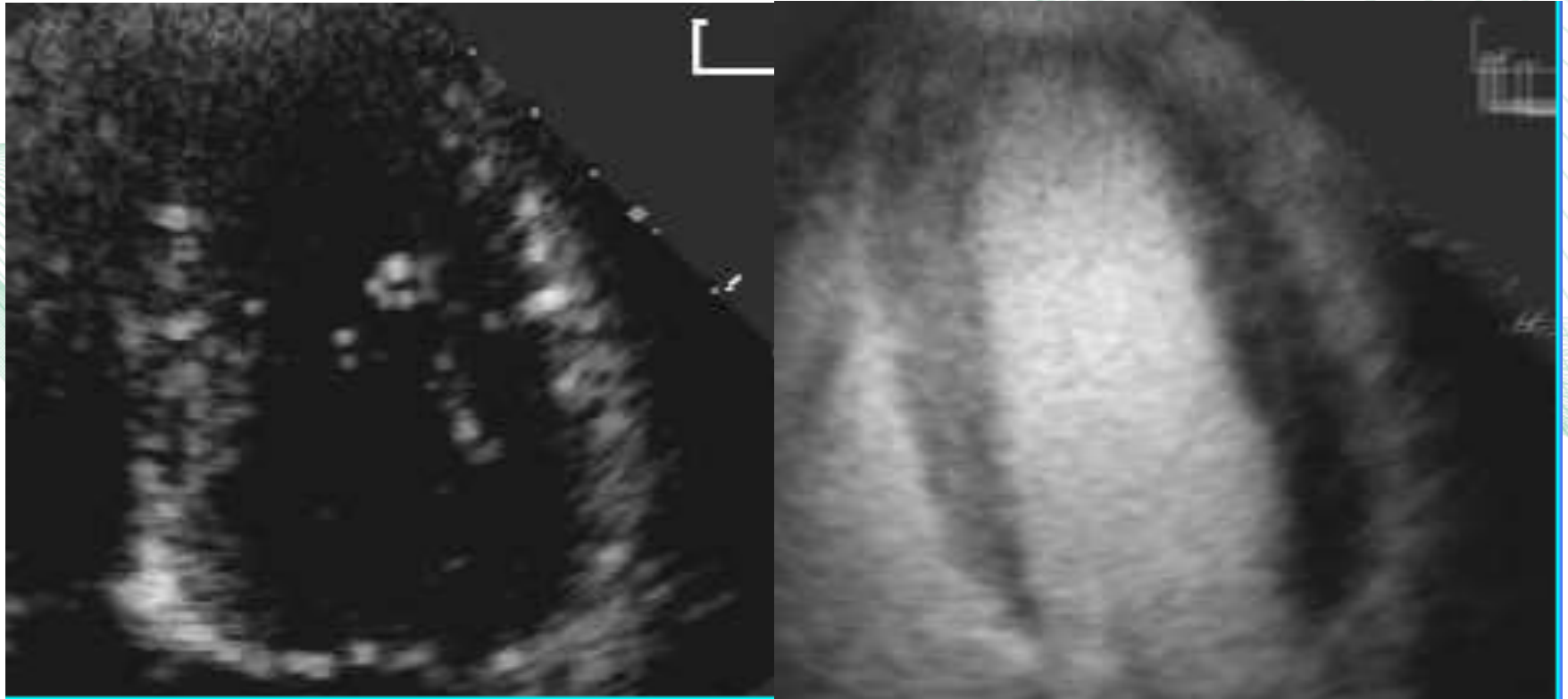
E.C Madu et al.

Cardiol Res 2011; 2(6); 259-268

- Chamber Opacification and Improved Endocardial Border Delineation
- Enhanced Recording of Doppler Signals
- Coronary Microcirculation
- Enhanced Delineation of Myocardial Perfusion

# Applicazioni Cliniche e Vantaggi

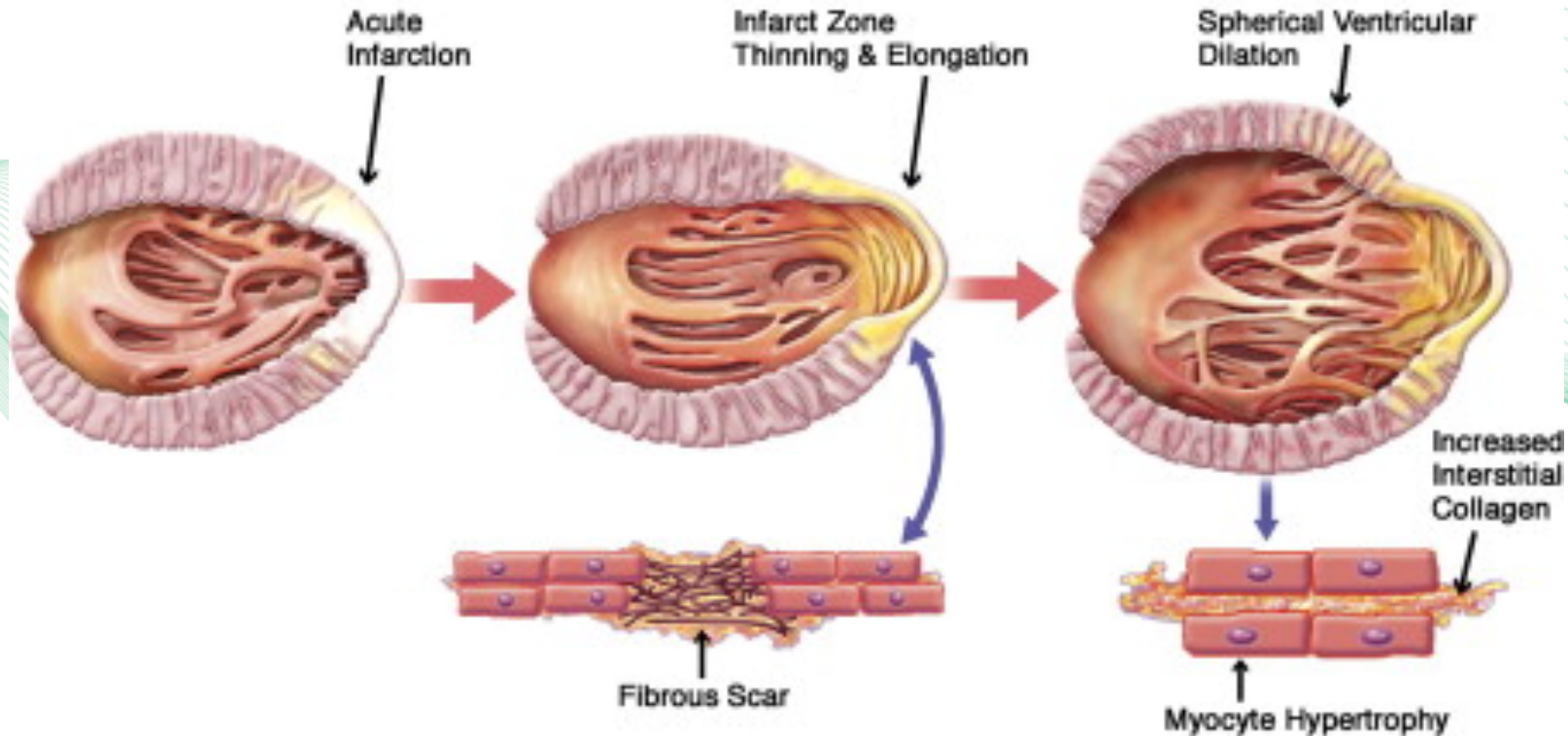
## Migliora la Delineazione del Bordo Endocardico



- ❑ Misurazioni più ACCURATE & RIPRODUCIBILI dei Volumi del VS & EF
- ❑ Maggior CONFIDENZA DIAGNOSTICA

# Rimodellamento post IMA

## POST-MI REMODELING



**LV remodelling factors:** size of infarction, location (anterior), transmural extent and necrosis, perfusional status of the infarct related artery, HF at the admission, viable myocardium, restrictive pattern of LV filling



# Improved prediction of outcome by contrast echocardiography determined left ventricular remodelling parameters compared to unenhanced echocardiography in patients following acute myocardial infarction

Girish Dwivedi, Rajesh Janardhanan, Sajad A. Hayat, Tiong K. Lim, and Roxy Senior\*

*Department of Cardiovascular Medicine, Northwick Park Hospital, Northwick Park Institute of Medical Research, Harrow, UK*

89 consecutive patients undergoing contrast echocardiography and unenhanced echocardiography 7 to 10 days after AMI and reperfusion therapy were followed up for cardiac death (CD) and AMI. LV ejection fraction (LVEF), LV end-systolic volume (ESV), and LV enddiastolic volume were assessed by the two methods independently. **LVEF and ESV with contrast echocardiography were found to be independent multivariable predictors of CD (P -0.04 and P -0.02, respectively) and CD or AMI (P -0.02 and P- 0.01, respectively).**



# Identificazione Malattia Coronarica: Metodiche a confronto

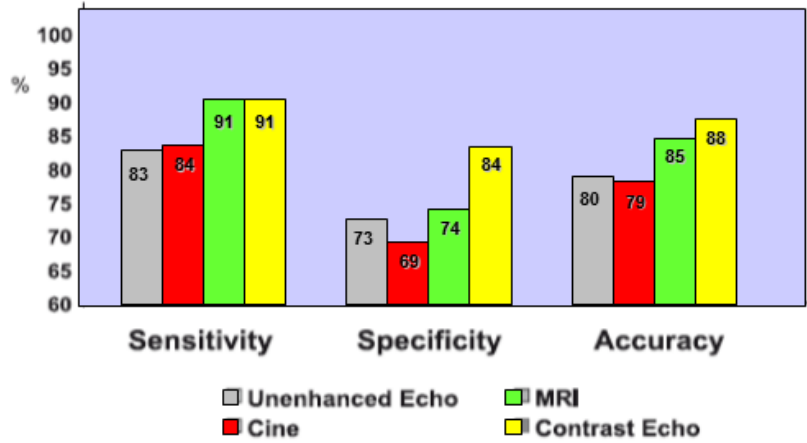
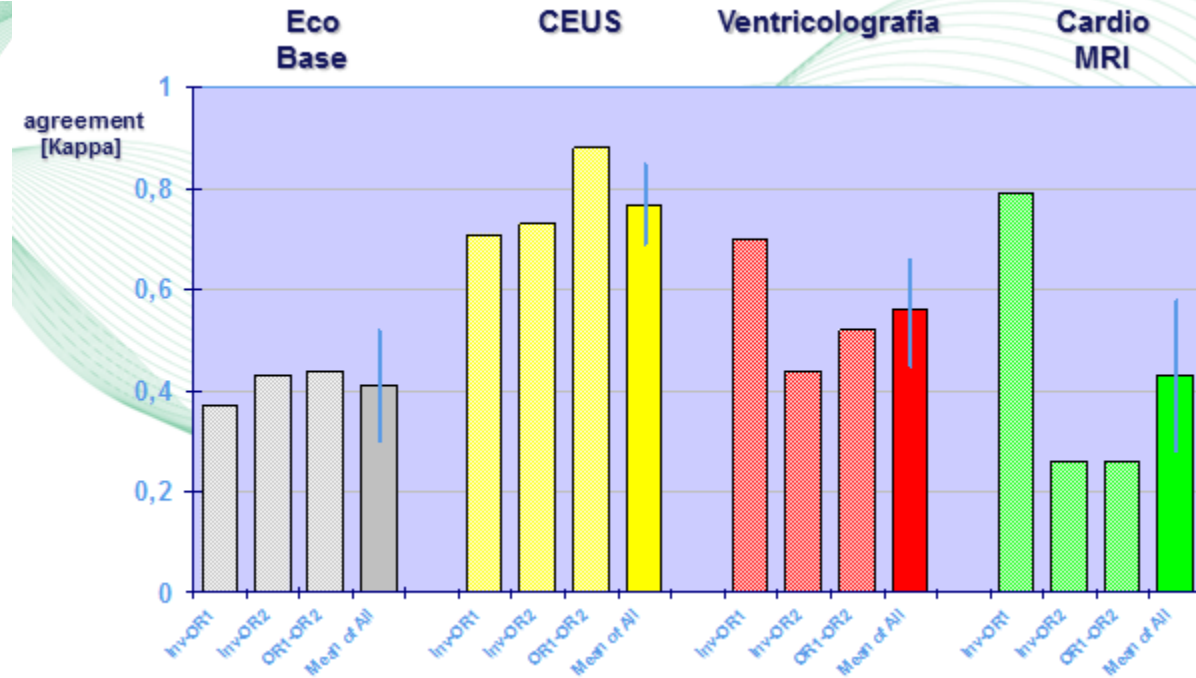


Fig. 4. Sensitivity, specificity and accuracy of the four imaging modalities to detect panel-defined wall motion abnormalities.

## Riproducibilità



Hoffmann R et al., Eur J Echocardiography  
7 (Suppl. 2), 2006, S16-S21

Many data have been published regarding the prognostic role of maintained vs absent tissue perfusion, i.e. viability, soon after an acute myocardial infarction (STEMI)

The demonstration of a significant amount of a/hypoperfused myocardial tissue predicts future cardiac events and heart failure



European Heart Journal (2008) 29, 299–314  
doi:10.1093/eurheartj/ehm621

REVIEW

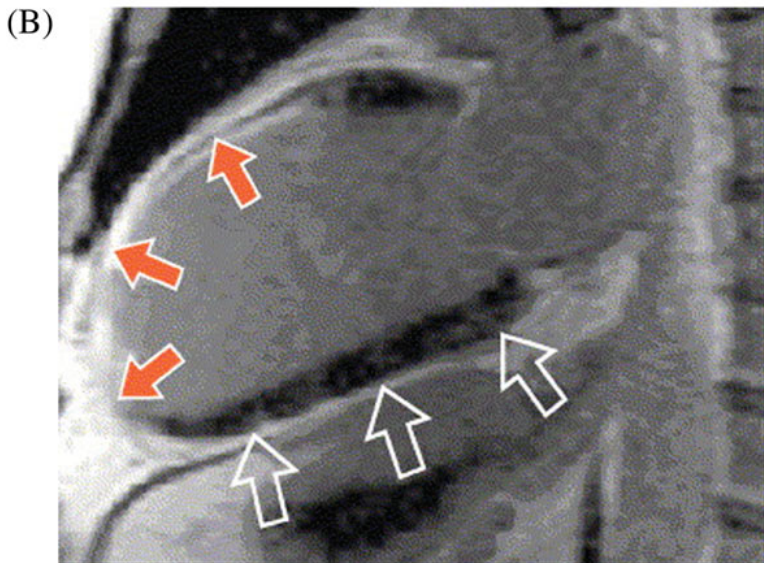
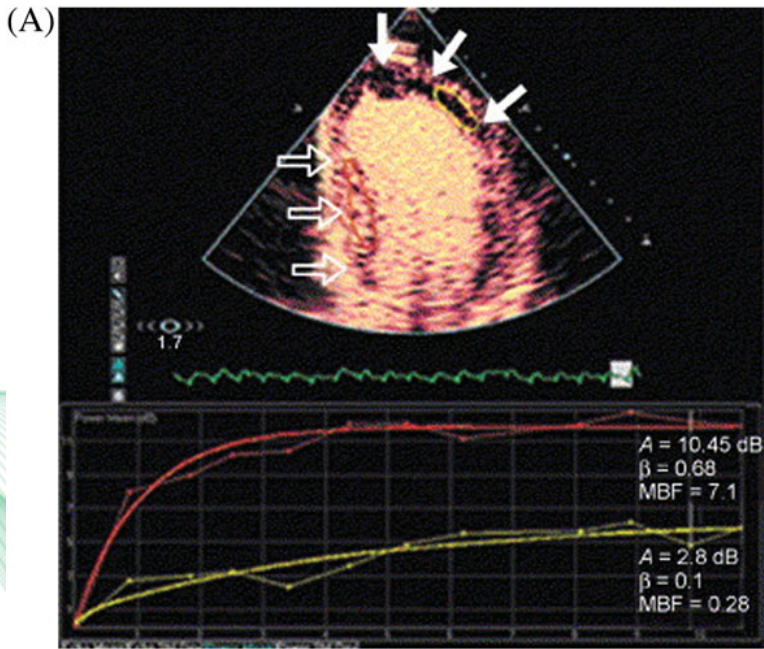
## Myocardial contrast echocardiography in ST elevation myocardial infarction: ready for prime time?

Sajad A. Hayat and Roxy Senior\*

Department of Cardiovascular medicine and Institute of Postgraduate Medical and Education Research, Northwick Park Hospital, Watford Road, Harrow HA1 3UJ, UK

**Figure 6** Example of a patient who sustained an anterior STEMI. (A) (top) Apical two-chamber view on MCE with absence of contrast opacification (solid arrows) at the apex and anterior wall, which were akinetic. The normal remote segments (outlined arrows) show normal contrast intensity. (A) (Bottom) replenishment curves in the akinetic segment (yellow) demonstrates very low peak contrast intensity (A), microbubble velocity ( $\beta$ ), and MBF, in comparison with remote normal segment (red). (B) The corresponding image on CMR demonstrates >75% TEI (delayed hyperenhancement) in the akinetic segments and no infarction in the remote normal segments

*Myocardial contrast echocardiography in ST elevation myocardial infarction: ready for prime time? Hayat SA, Senior R. Eur Heart J. 2008 Feb;29(3):299-314. Review*



# Myocardial contrast echocardiography accurately reflects transmural extent of myocardial necrosis and predicts contractile reserve after acute myocardial infarction

Rajesh Janardhanan, MD, MRCP,<sup>a</sup> James C. C. Moon, MRCP,<sup>b</sup> Dudley J. Pennell, MD, FRCP, FESC, FACC,<sup>b</sup> and Roxy Senior, MD, DM, FRCP, FESC, FACC<sup>a</sup> *Harrow and London, United Kingdom*

Scar tissue shows minimal/absent rest perfusion  
 MCE has high spatial resolution (2mm), ideal to address myocardial necrosis *transmurality*, by means of absent/present tissue perfusion  
 MCE correlates almost perfectly with late-enhancement by Gd-CMR

**Table III.** Accuracy of MCE and CMR to predict contractile reserve

Test for contractile reserve	Sensitivity	Specificity	PPV	NPV	Accuracy
Normal perfusion on MCE	73%	96%	89%	88%	88%
Normal/reduced perfusion on MCE	82%	83%	70%	90%	82%
≤25% TEI	60%	97%	91%	83%	85%
≤50% TEI	67%	92%	80%	85%	84%
≤75% TEI	79%	62%	50%	86%	67%

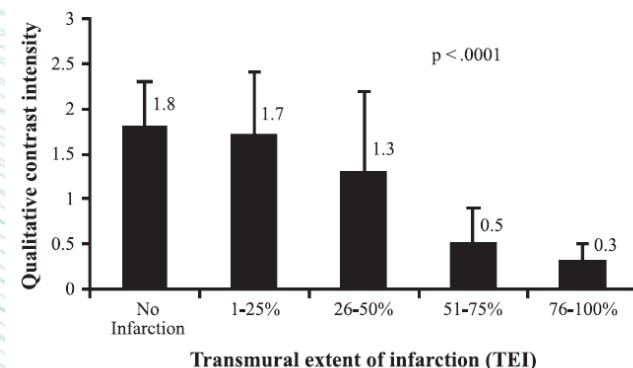
**Table IV.** Relationship between quantitative MCE parameters, TEI, and contractile reserve

	Normal segments	Dysfunctional segments with contractile reserve	Dysfunctional segments without contractile reserve
Mean peak video intensity (A)	7.94 ± 2.20	6.68 ± 1.92 <sup>a</sup>	3.65 ± 1.35 <sup>b</sup>
Mean β	1.05 ± 0.60	0.76 ± 0.40 <sup>c</sup>	0.25 ± 0.07 <sup>b</sup>
Mean MBF (A × β)	7.64 ± 3.89	5.21 ± 3.23 <sup>d</sup>	0.98 ± 0.58 <sup>b</sup>
Mean TEI score	0	1.4 <sup>e</sup>	3.56 <sup>b</sup>
Contractile reserve score	1	1.20 <sup>a</sup>	2.85 <sup>b</sup>

Contractile reserve score: mean systolic wall thickening score during dobutamine.

<sup>a</sup>P = .05 (vs normal segments).  
<sup>b</sup>P < .0001 (vs segments with contractile reserve).  
<sup>c</sup>P = .03 (vs normal segments).  
<sup>d</sup>P = .01 (vs normal segments).  
<sup>e</sup>P < .0001 (vs normal segments).

**Figure 1**



Variation in the qualitative contrast intensity on MCE with increasing TEI in the dysynergic segments.

## The Extent of Microvascular Damage During Myocardial Contrast Echocardiography Is Superior to Other Known Indexes of Post-Infarct Reperfusion in Predicting Left Ventricular Remodeling

Results of the Multicenter AMICI Study

Leonarda Galiuto, MD, PhD, FACC,\* Barbara Garramone, MD,\* Antonio Scarà, MD,\* Antonio G. Rebuzzi, MD,\* Filippo Crea, MD, FACC,\* Giuseppe La Torre, MD, MSc,† Stefania Funaro, MD,‡ Mariapina Madonna, MD,§ Francesco Fedele, MD,§ Luciano Agati, MD,§

**Table 4.** Prediction of Recovery of Regional and Global Function and Prediction of Events by MCE in Patients After Acute Myocardial Infarction

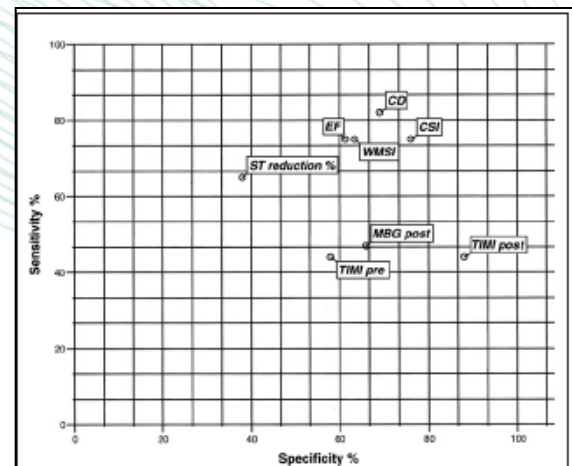
Regional Function	Patients (n)	FU (months)	Sensitivity	Specificity	PPV	NPV	Accuracy
Bolognese et al. (53)	30	1	96%	18%	41%	89%	47%
Agati et al. (59)*	23	2	100%	90%	81%	100%	93%
Swinburn et al. (58)*	96	3-6	59%	76%	47%	84%	UN
Main et al. (60)	34	2	77%	83%	90%	63%	79%
Hillis et al. (55)	37	2	80%	67%	66%	81%	73%
Janardhanan et al. (56)	50	3	87%	78%	65%	93%	81%
Korosoglou et al. (57)	32	1	81%	88%	95%	61%	83%
Huang et al. (63)	34	4	83%	82%	92%	66%	83%
Nunes Sbrano et al. (61)	50	6	95%	52%	55%	94%	68%
Abe et al. (41)	21	6	98%	32%	43%	96%	55%
Pooled estimate	407		81%	69%	64%	83%	74%

Global Function and Events	Patients (n)	Reflow Group			No-Reflow Group		
		EF Baseline	EF FU	FU (% Cardiac Death)	EF Baseline	EF FU	FU (% Cardiac Death)
Ito et al. (51)	39	42 ± 11	56 ± 13		35 ± 9	43 ± 9	
Porter et al. (52)	45	59 ± 10	63 ± 9		55 ± 13	46 ± 5	
Sakuma et al. (48)	50	44 ± 9	56 ± 12	4%	35 ± 18	45 ± 14	12%
Bolognese et al. (47)	124	40 ± 7	51 ± 11	3%	33 ± 8	NA	25%

Note: data are presented as percentage. \*Patients partly revascularized.

EF = ejection fraction; FU = follow-up; NPV = negative predictive value; PPV = positive predictive value; UN = unknown.



**Figure 2** Prediction of Left Ventricular Remodeling

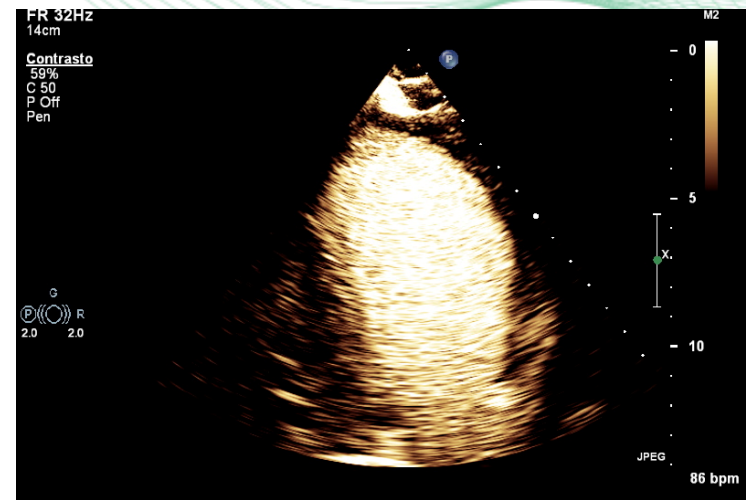
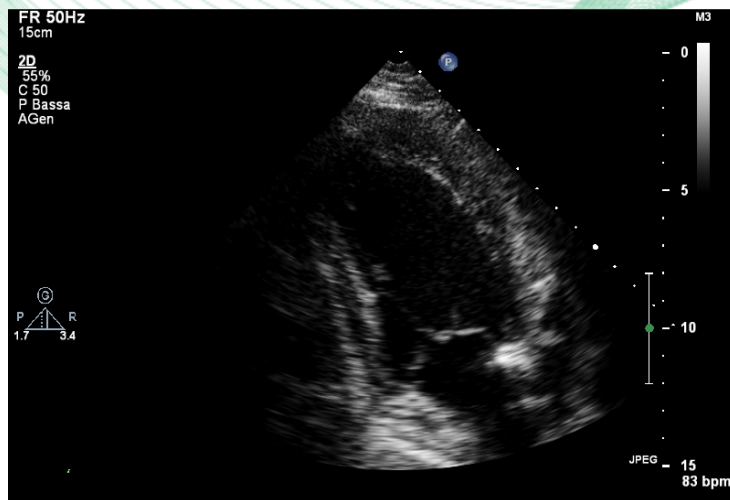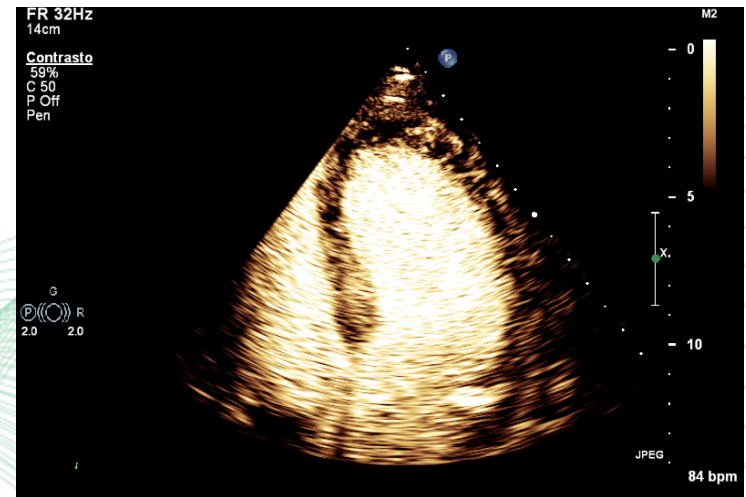
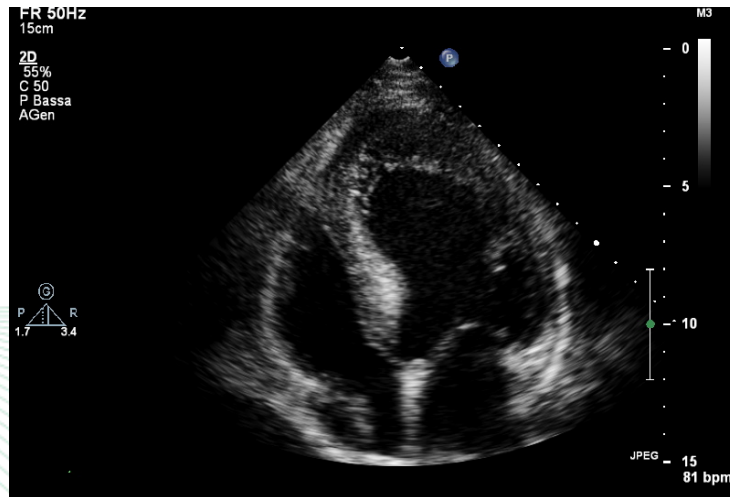
Sensitivity and specificity of different parameters studied in the prediction of left ventricular remodeling. CD = contrast defect; CSI = contrast score index; EF = ejection fraction; MBG = myocardial blush grade; TIMI = Thrombolysis in Myocardial Infarction; WMSI = wall motion score index.

### Conclusions

Among patients with TIMI flow grade 3, the extent of microvascular damage, detected and quantitated by MCE, is the most powerful independent predictor of LV remodeling after STEMI as compared with persistent ST-segment elevation and myocardial blush grade. (J Am Coll Cardiol 2008;51:552-9) © 2008 by the American College of Cardiology Foundation

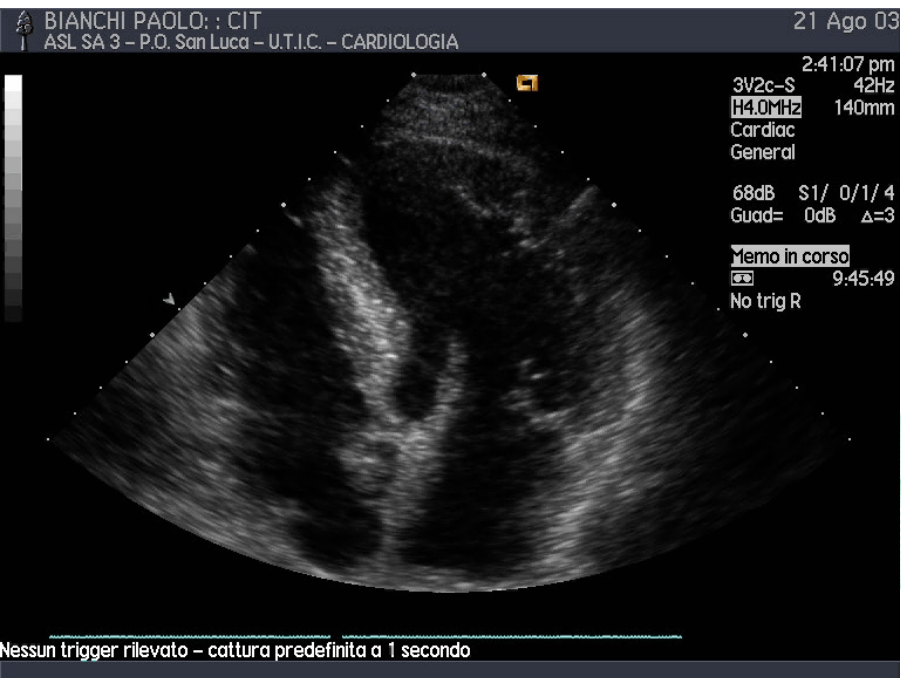
# Coronary angio apparently shows good reflow after PCI

## Suspected thrombus with standard echo 5 days after revascularization



**CEUS not only excludes the suspected apical thrombus, but also highlights the absence of mid and apical tissue perfusion**  
**TISSUE-LEVEL NO-REFLOW**

*per cortesia di  
Nicola Gaibazzi,  
Centro Cuore AOU-Parma*

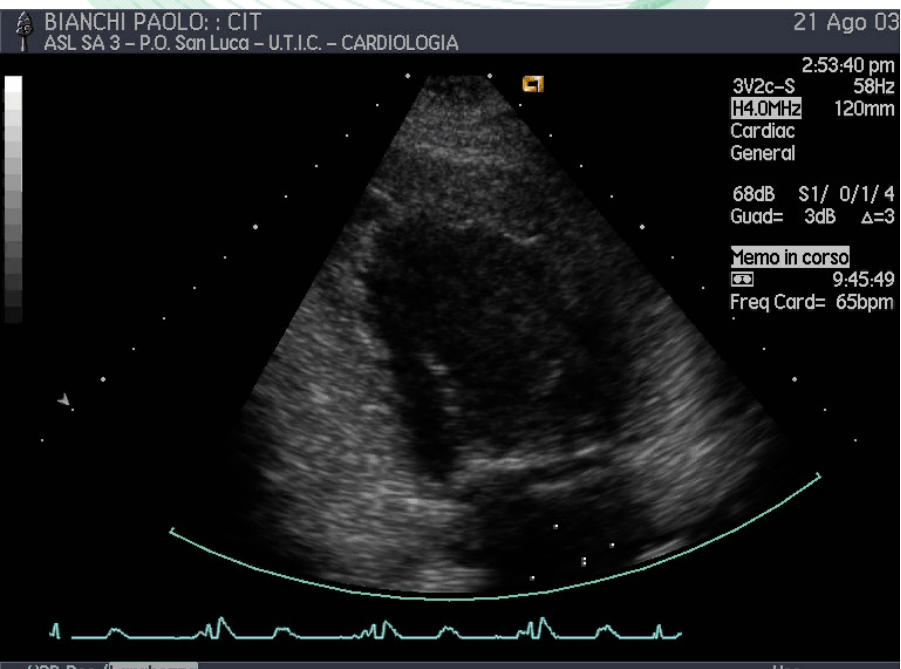


# ANT STEMI

EDV = 112 ml

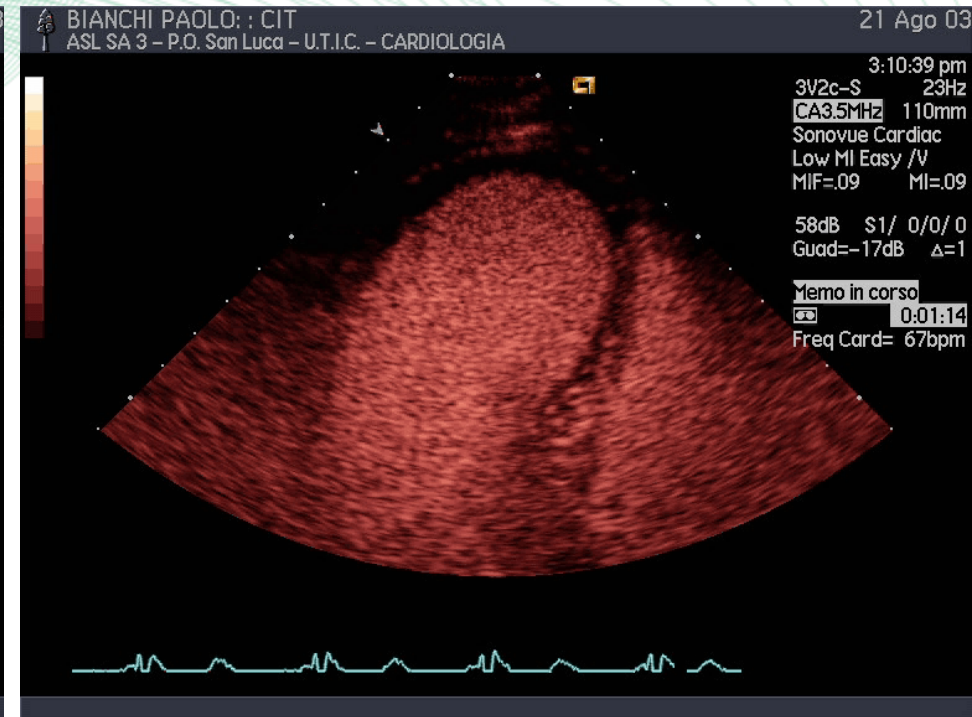
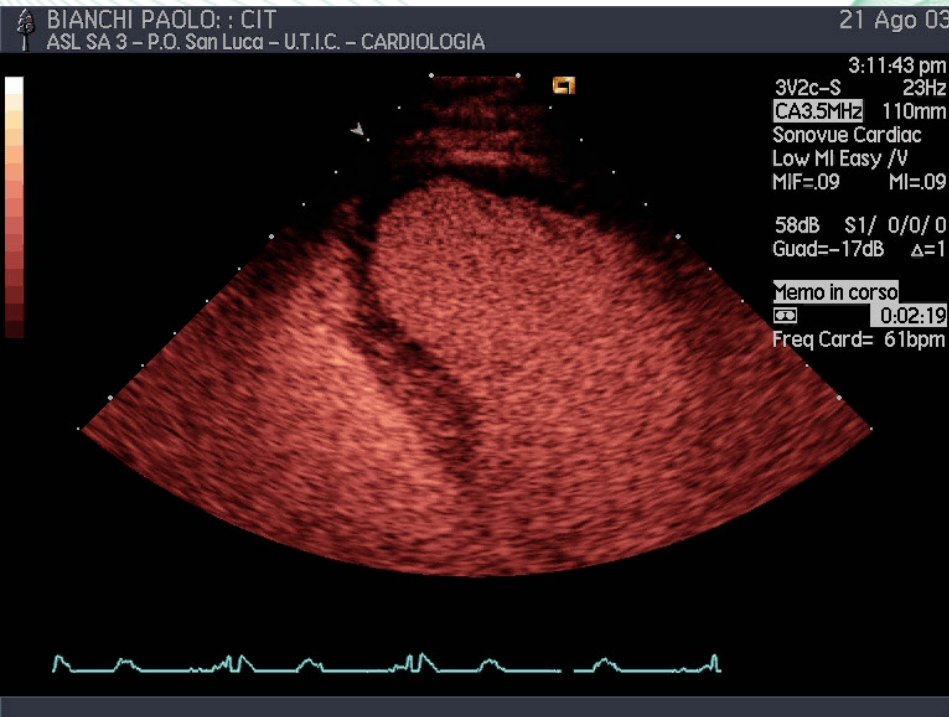
ESV = 61 ml

LVEF = 44 %

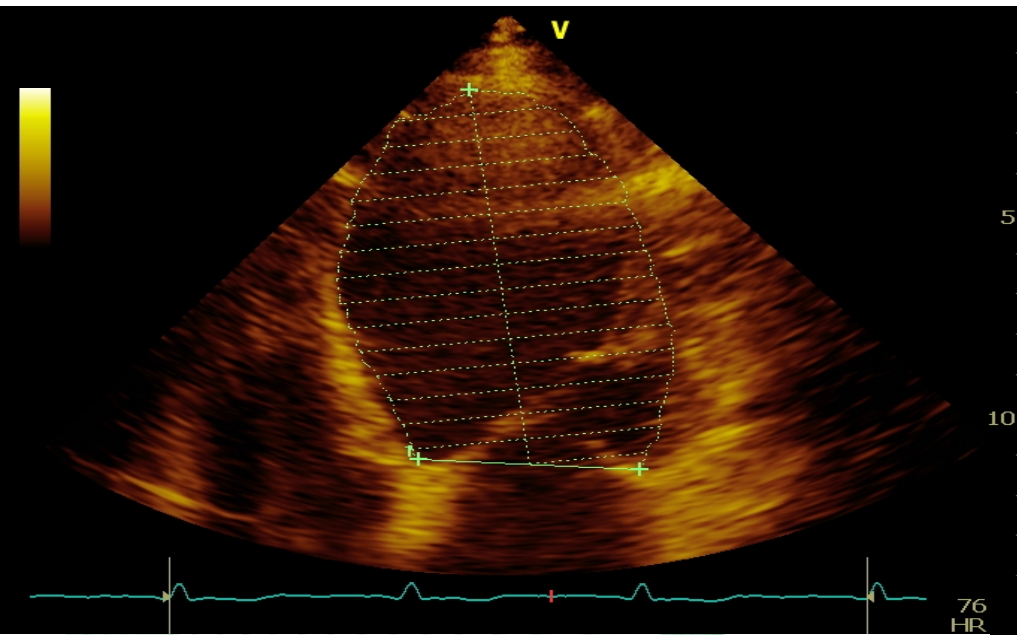


*Per cortesia da Rodolfo Citro, Salerno*

# MCE post AMI

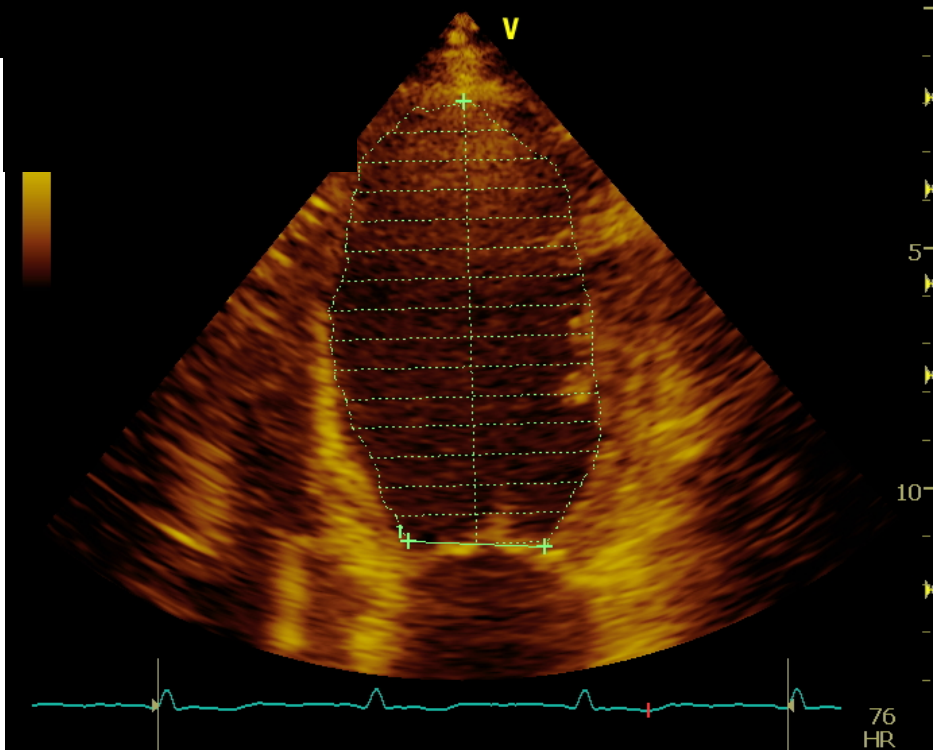


*Per cortesia da Rodolfo Citro, Salerno*



**EDV = 198 ml**  
**ESV = 146 ml**  
**LV EF = 26%**

**Two years later...**



*Per cortesia da Rodolfo Citro, Salerno*



# Opacificazione e perfusione: diagnosi di trombi e masse

## ASE CONSENSUS STATEMENT

### American Society of Echocardiography Consensus Statement on the Clinical Applications of Ultrasonic Contrast Agents in Echocardiography

Sharon L. Mulvagh, MD, FASE, Chair, Harry Rakowski, MD, FASE, Co-Chair, Mani A. Vannan, MBBS, Co-Chair, Sahar S. Abdelmoneim, MD, MSc, Harald Becher, MD, PhD, S. Michelle Bierig, MPH, RDCS, FASE, Peter N. Burns, PhD, Ramon Castello, MD, FASE, Patrick D. Coon, RDCS, FASE, Mary E. Hagen, RDCS, RN, James G. Jollis, MD, Thomas R. Kimball, MD, FASE, Dalane W. Kitzman, MD, Itzhak Kronzon, MD, FASE, Arthur J. Labovitz, MD, FASE, Roberto M. Lang, MD, FASE, Joseph Mathew, MD, FASE, W. Stuart Moir, MBBSc, Sherif F. Nagueh, MD, Alan S. Pearlman, MD, FASE, Julio E. Perez, MD, FASE, Thomas R. Porter, MD, FASE, Judy Rosenbloom, RDCS, FASE, G. Monet Strachan, RDCS, FASE, Srihari Thanigaraj, MD, FASE, Kevin Wei, MD, Anna Woo, MD, Eric H. C. Yu, MD, and William A. Zoghbi, MD, FASE,

## **Clinical applications**

### **1. Assessment of Cardiac Structure and Function**

i. Quantification of LV volumes (LVO) and LVEF

ii. Cardiac anatomy

° Apical hypertrophy

° Noncompaction

° Thrombus

° Endomyocardial fibrosis

° LV apical ballooning

° LV aneurysm and pseudoaneurysm

### **iii. To identify and characterize intracardiac masses**

iv. Extracardiac anatomy

° Vascular imaging: aortic dissection, other acute aortic syndromes, femoral arterial pseudoaneurysms

v. Doppler enhancement

### **2. Contrast Enhancement in Stress Echocardiography**

### **3. Echocardiography in the Emergency Department**

**4.5.6. Contrast Agent Use : in ICU, in Cardiac Interventional Therapy, in Pediatric Echocardiography (not approved by the FDA, contraindication for significant intracardiac shunts)**

### ***iii. To identify and characterize intracardiac masses***

Esistono 3 tipi di risposta a tale infusione che **DISTINGUE** le masse:

- 1) Contrast no enhanced** (masse non vascolarizzate) :  
trombo
- 2) Contrast hypoenhanced** (ridotta vascolarizzazione) :  
mixoma
- 3) Contrast hyperenhanced** ( altamente vascolarizzati):  
tumori maligni

# Differential Diagnosis of Cardiac Masses Using Contrast Echocardiographic Perfusion Imaging

James N. Kirkpatrick, MD, Tiffany Wong, MD, James E. Bednarz, BS, RDCS,  
Kirk T. Spencer, MD, FACC, Lissa Sugeng, MD, R. Parker Ward, MD, FACC,  
Jeanne M. DeCara, MD, FACC, Lynn Weinert, BS, Thomas Krausz, MD, FRCPATH,  
Roberto M. Lang, MD, FACC

*Chicago, Illinois*

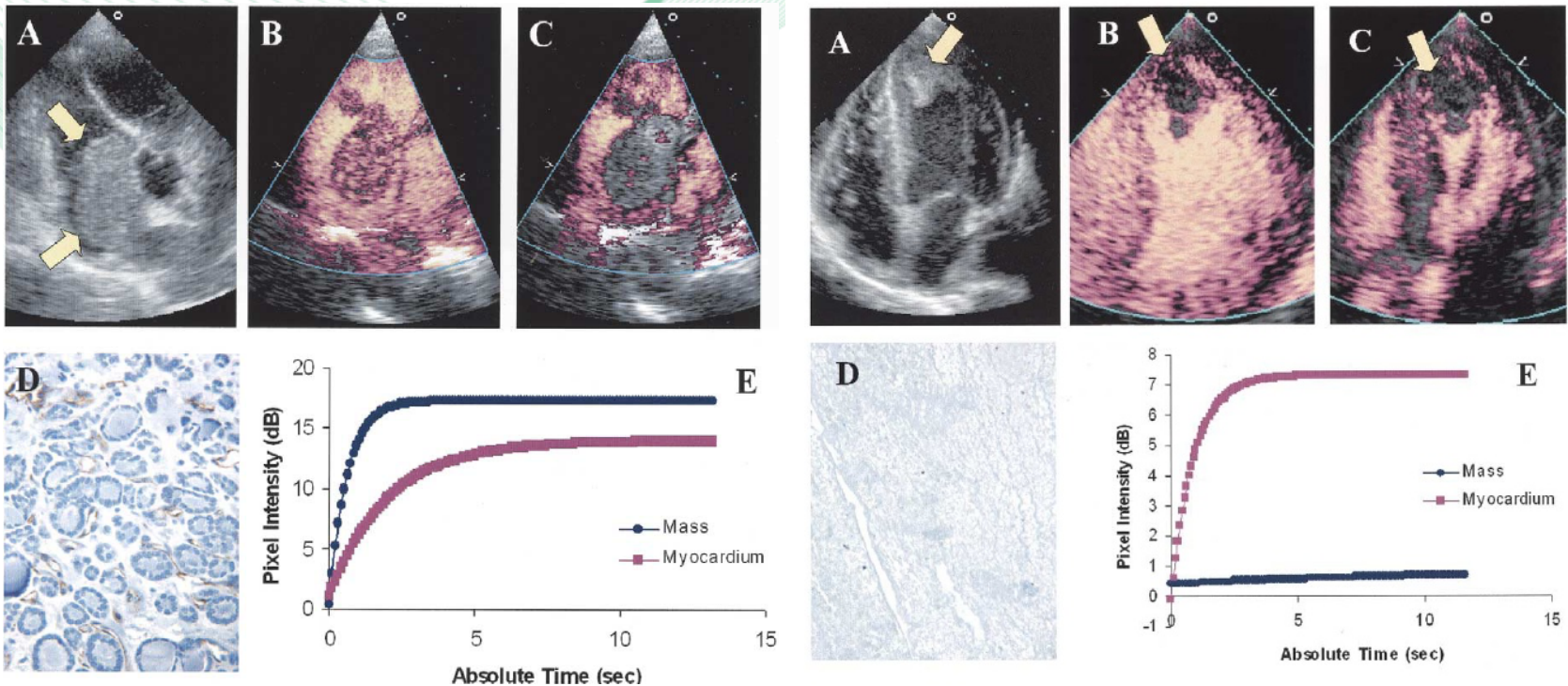
## **CONCLUSIONS**

Echocardiographic contrast perfusion imaging aids in the differentiation of cardiac masses. Compared with the adjacent myocardium, malignant and vascular tumors hyper-enhanced, whereas stromal tumors and thrombi hypo-enhanced. (J Am Coll Cardiol 2004;43:1412–9)

© 2004 by the American College of Cardiology Foundation

## TECNICA

- Si esegue infusione continua di 1ml/min di mdc da accesso venoso periferico
  - Setting ecocardiografico adeguato per perfusione con basso MI (di solito 0,1-0,2)
  - Si assiste all' opacizzazione nei primi frame delle sezioni destre, sinistre e successivamente si assiste alla opacificazione dell' eventuale massa vascolarizzata
- Allo steady state si può applicare un impulso ad alto MI (1-1,6) "flash" per 10 sec per verificare il replenishment della massa e confrontare la perfusione con il miocardio adiacente



## Usefulness of contrast echocardiography for assessment of intracardiac masses

Intérêt de l'échocardiographie de contraste dans l'étude des masses intracardiaques

Nicolas Mansencal\*, Laure Revault-d'Allonnes,  
Jean-Pierre Pelage, Jean-Christian Farcot,  
Pascal Lacombe, Olivier Dubourg

*Results.* – Using contrast echocardiography, an accurate diagnosis was made in all patients by an experienced investigator and in all patients except one (97%), by a physician trainee ( $p = 0.31$ ). Among patients with a history of tumor, echocardiography allowed accurate diagnosis of the nature of the mass in all patients; 50% of these patients presented with a secondary cardiac tumor and the others had a thrombus. Of the 14 patients with a thrombus located in the left ventricle, 12 (86%) presented with left ventricular motion abnormalities using conventional echocardiography, whereas wall motion abnormalities were observed in all 14 patients (100%) using contrast agent. In these patients, 91 and 99% of left ventricular segments were well visualized using conventional and contrast echocardiography, respectively ( $p < 0.0001$ ).

*Conclusions.* – Contrast echocardiography may be useful for the tissue characterization of intracardiac masses.

## GUIDELINES AND STANDARDS

### Guidelines for the Cardiac Sonographer in the Performance of Contrast Echocardiography: A Focused Update from the American Society of Echocardiography

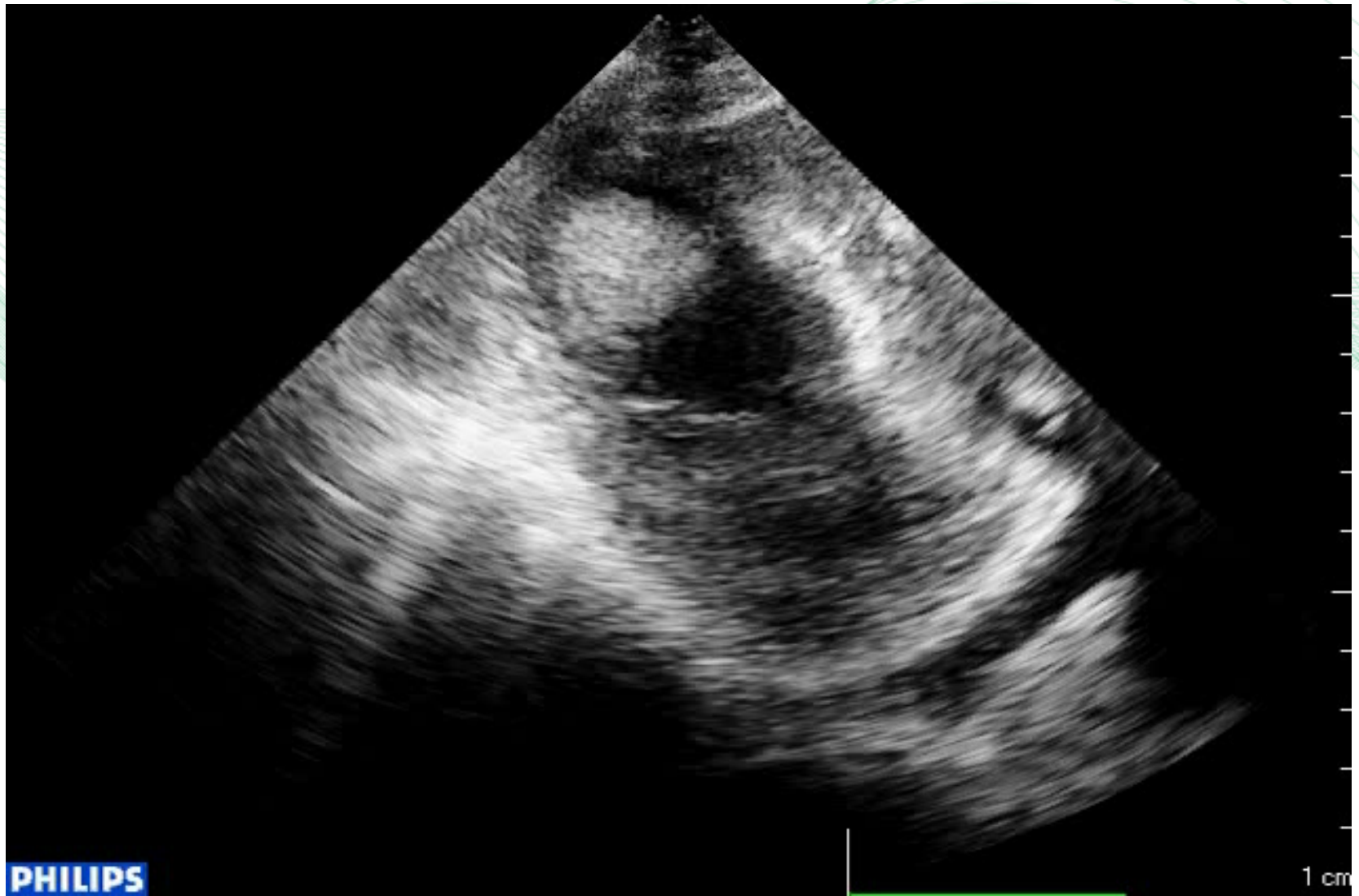To differentiate a thrombus from an intracardiac tumor, real-time very low MI perfusion imaging with high-MI flash should be used if available.<sup>9</sup> Thrombi are avascular and show no contrast enhancement after a high-MI flash impulse, as opposed to tumors, which may be either poorly (benign stromal tumors, such as myxoma) or highly (malignant tumors) vascularized and will demonstrate proportional degrees of perfusion by flash replenishment real-time very low MI

If very low MI software is not available, low-MI ( $<0.3$ ) harmonic imaging can be deployed to visualize whether contrast enhancement is occurring within the mass and aid in the differentiation of cardiac masses.

## Caso Clinico 1

paziente 65 aa sesso M, affetto da neoplasia polmonare in stadio avanzato con ripetizioni mediastiniche, pregresso infarto miocardico anteriore (1/2008)

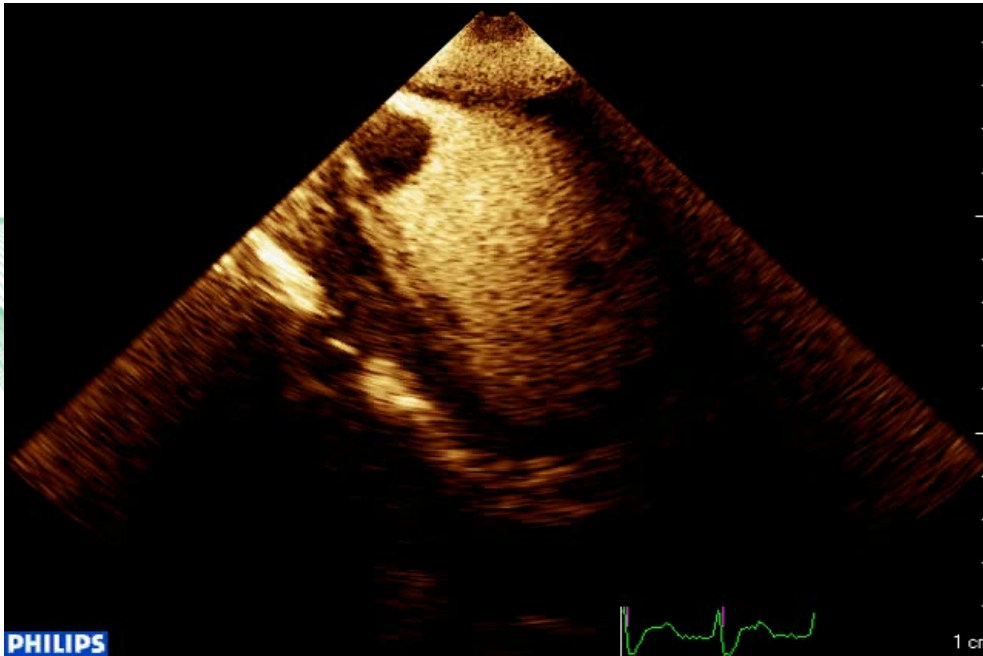
Riscontro di massa intraventricolare apicale..... TROMBO VS ETEROPLASIA?



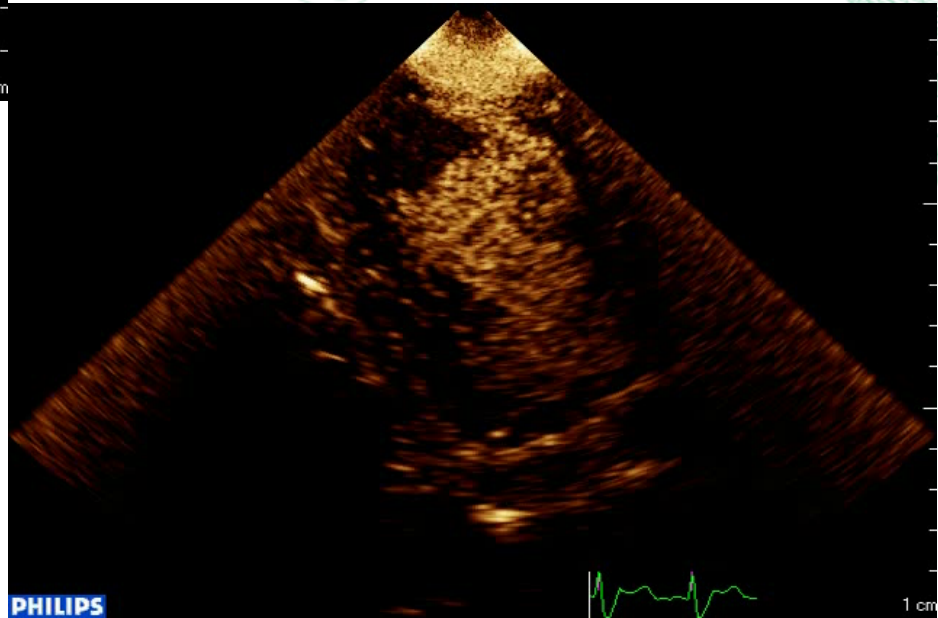

.....dopo 1min dall' iniezione ev periferica di mdc

**1) Contrast no enhanced  
(masse non vascolarizzate) : trombo**



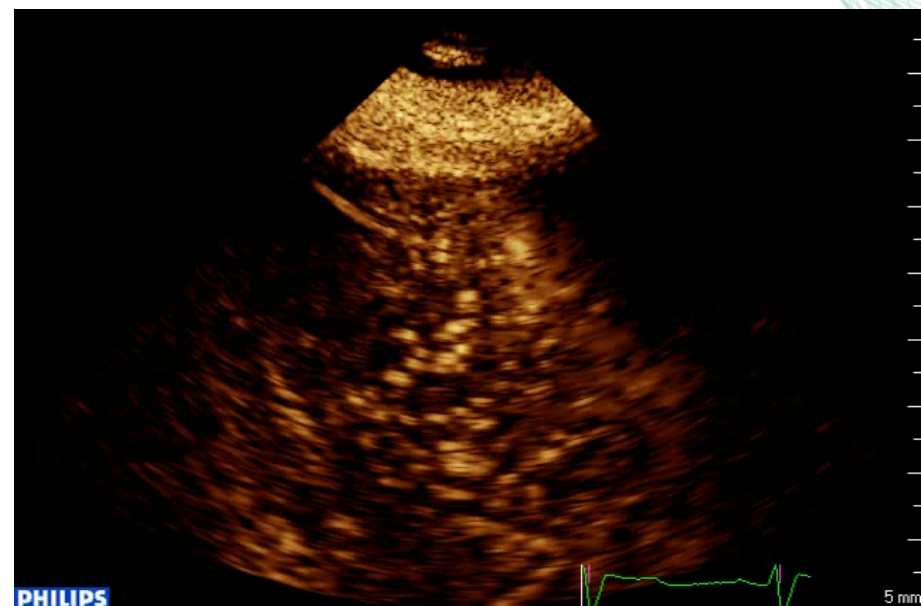
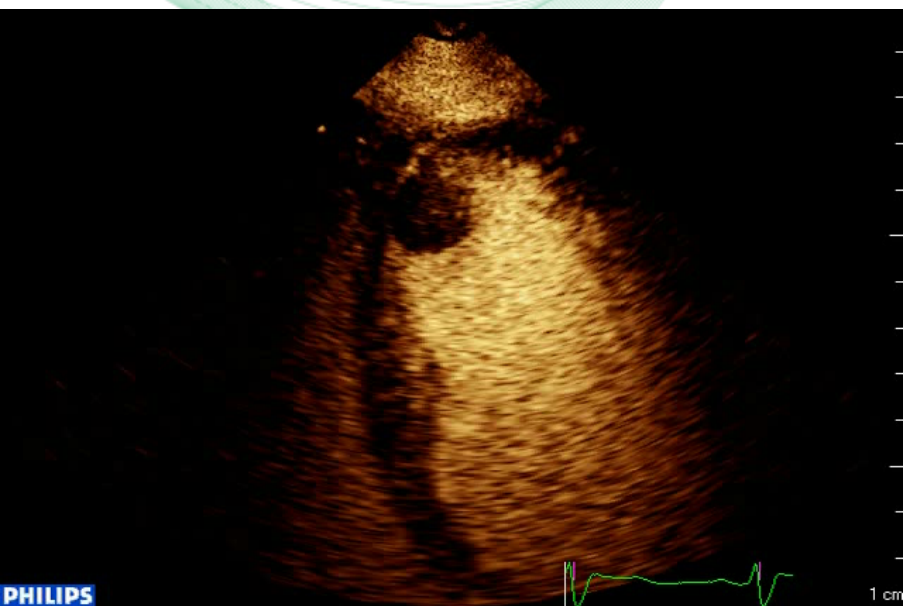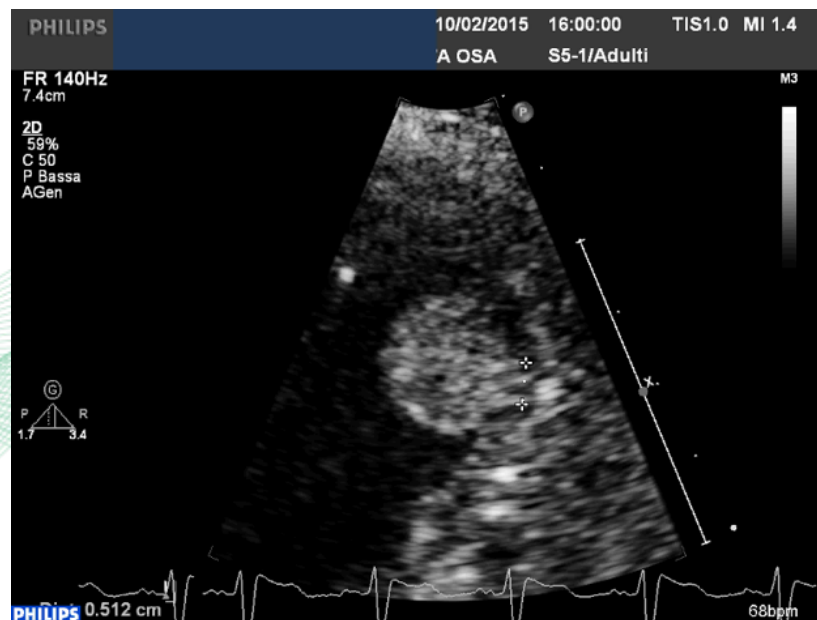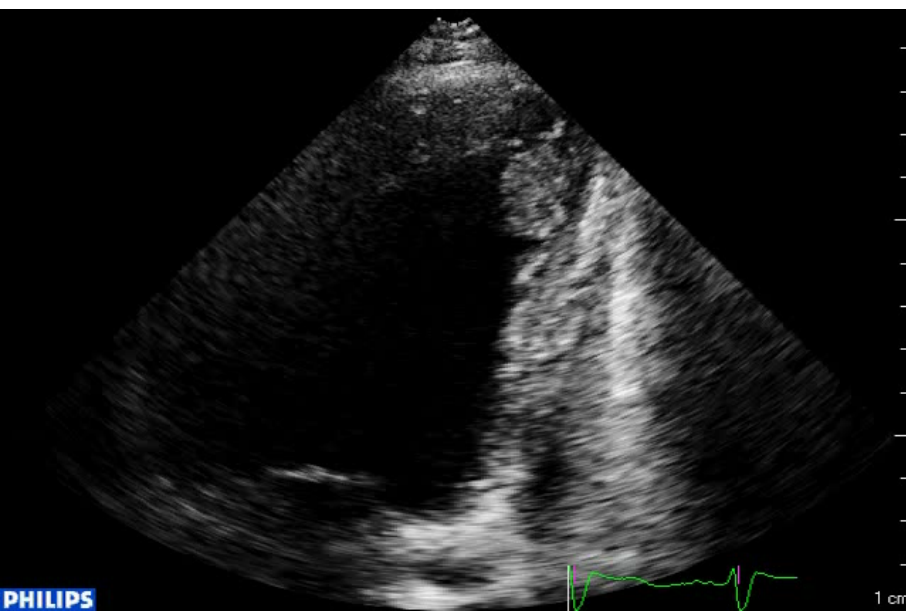
.....dopo 3 min dall' iniezione ev periferica di mdc



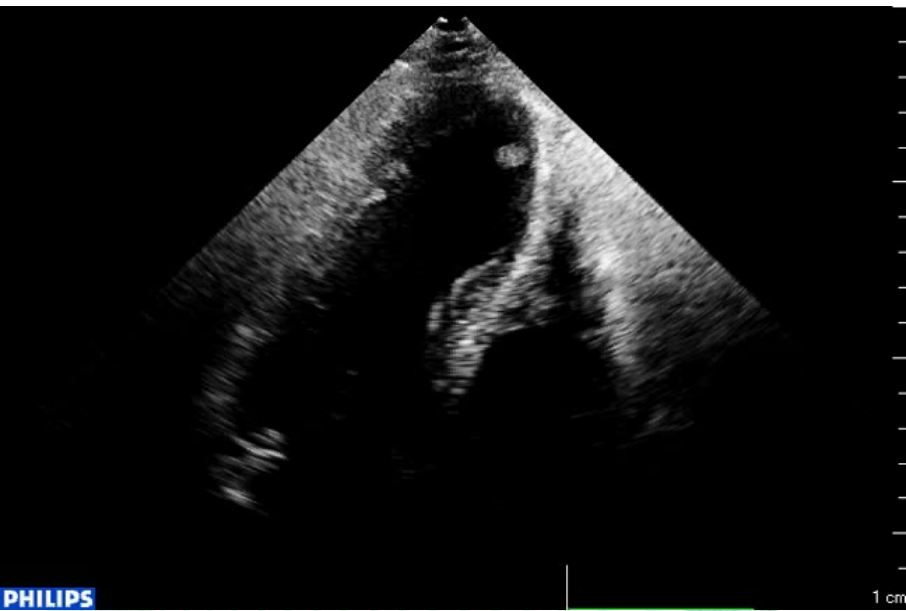**“Value of contrast echocardiography for left ventricular thrombus detection post infarction and impact on antithrombotic therapy”**

*Hans-Marc J Siebelink, Arthur J.H.A Scholte et al  
Cor. Art Diseases 2009,20:462-466*

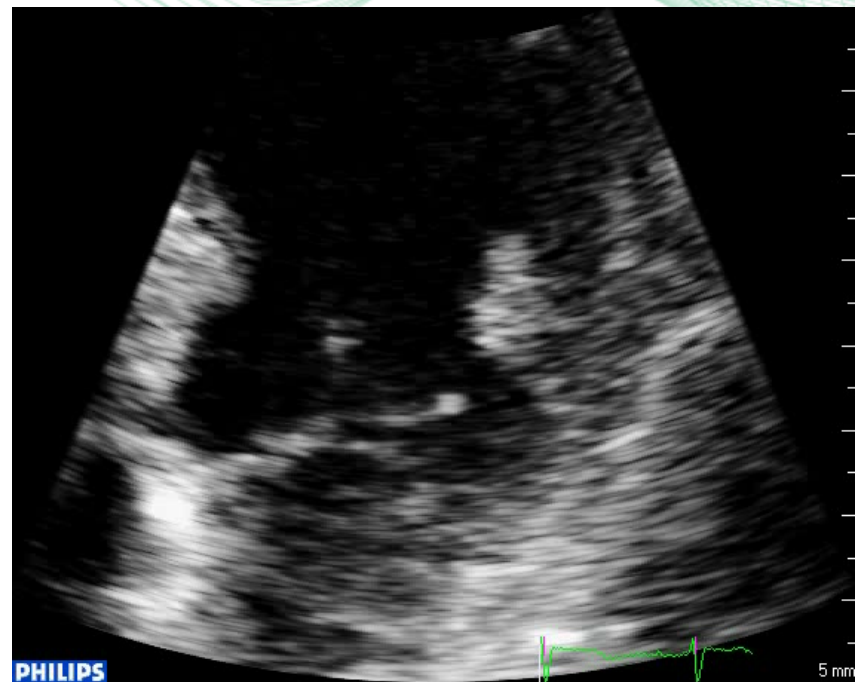
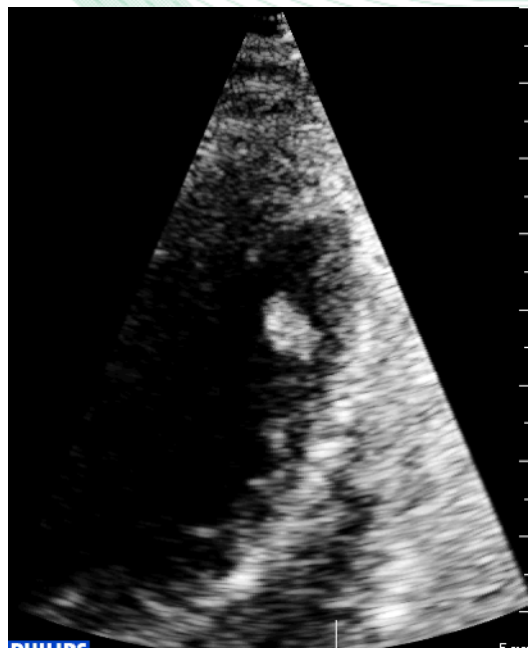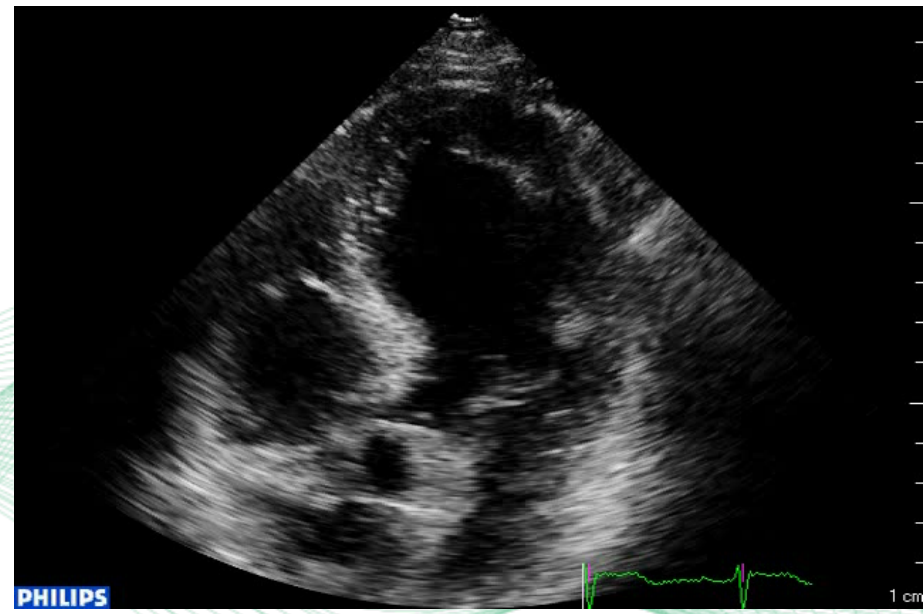
# 1) Contrast no enhanced (masse non vascolarizzate) : trombo



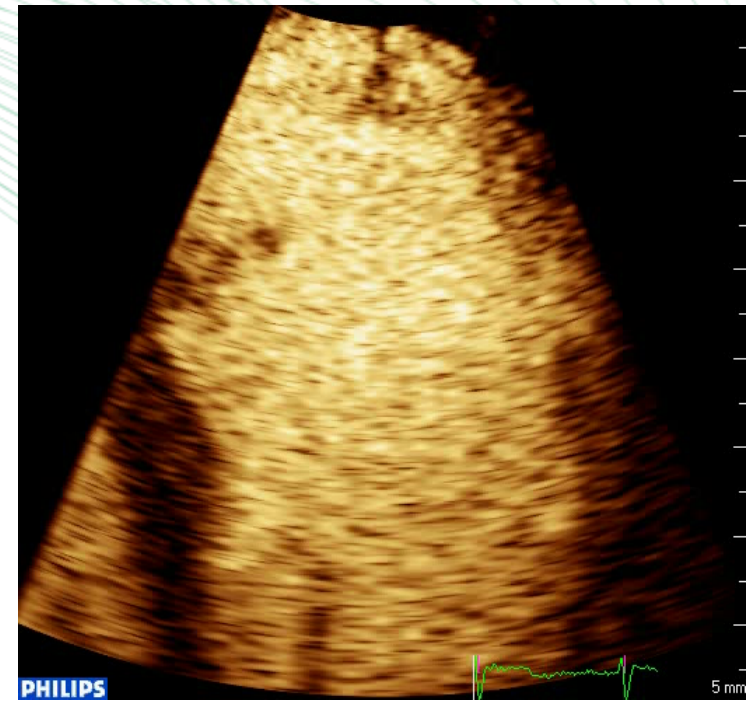
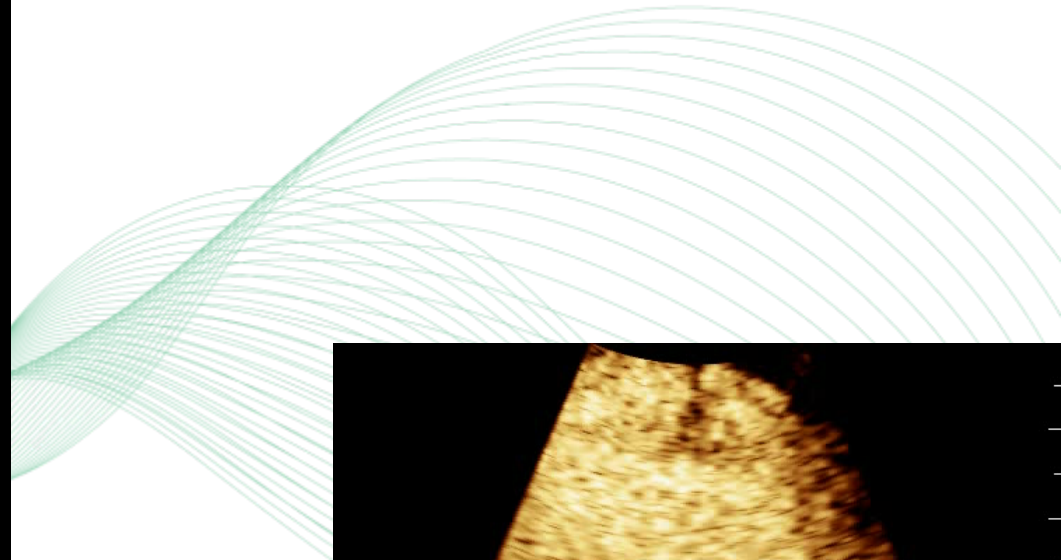
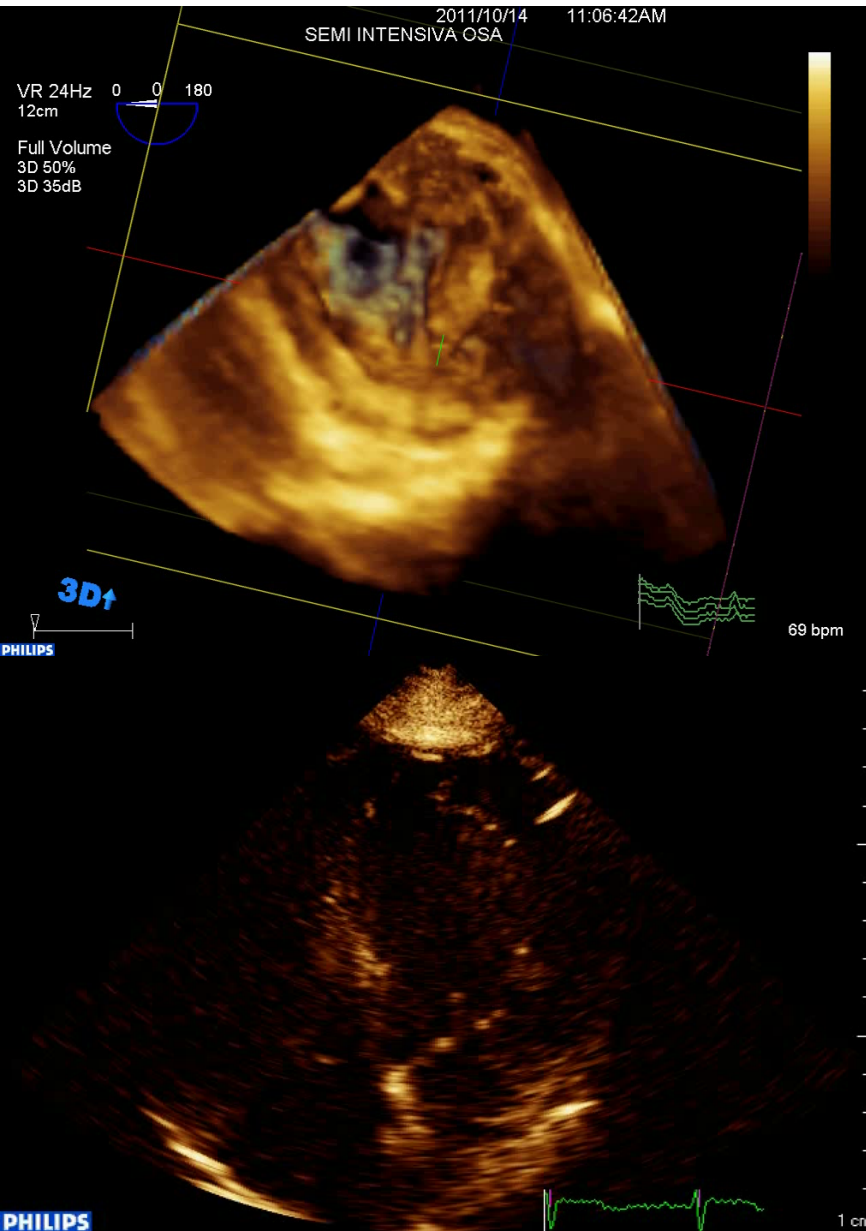
Caso 2 : Tako-Tsubo



Caso 3: ictus ischemico



# 1) Contrast no enhanced: fibroelastoma papillare



Very Low MI: 0.15

EXPERT  
REVIEWS

# Cardiac tumors: the role of cardiovascular imaging

*Expert Rev. Cardiovasc. Ther.* Early online, 1–7 (2014)

Sanjeev Bhat tacharyya<sup>1</sup>,  
Rajdeep S Khattar<sup>1</sup>,  
Dorothy M Gujral<sup>2</sup> and  
Roxy Senior<sup>3,4</sup>\*

<sup>1</sup>Royal Brompton Hospital, Sydney St,

London SW2 6NP, UK

<sup>2</sup>Royal Marsden Hospital, Fulham Road,

London, SW2 6JJ, UK

<sup>3</sup>Northwick Park Hospital, Harrow,

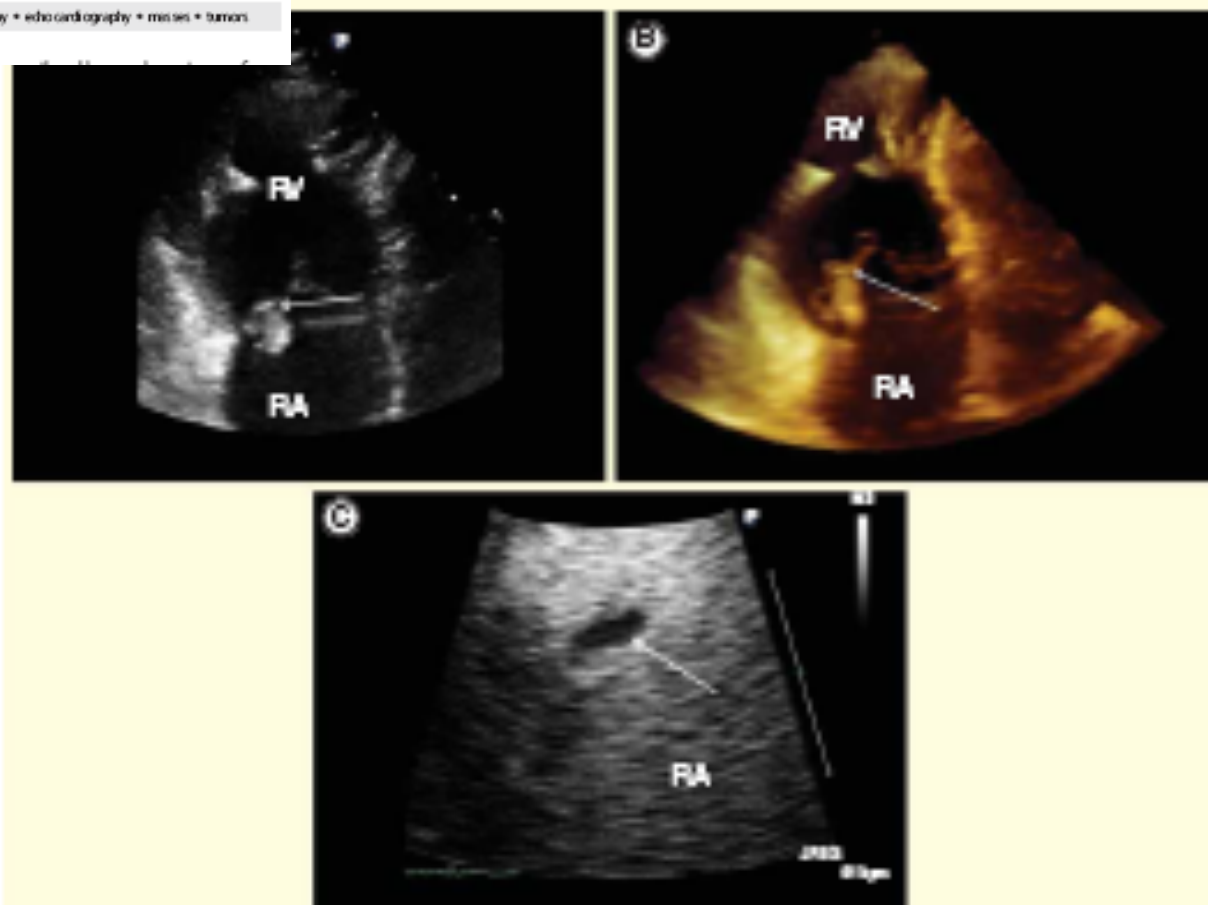
Middlesex, HA1 2UJ, UK

\*Author for correspondence:

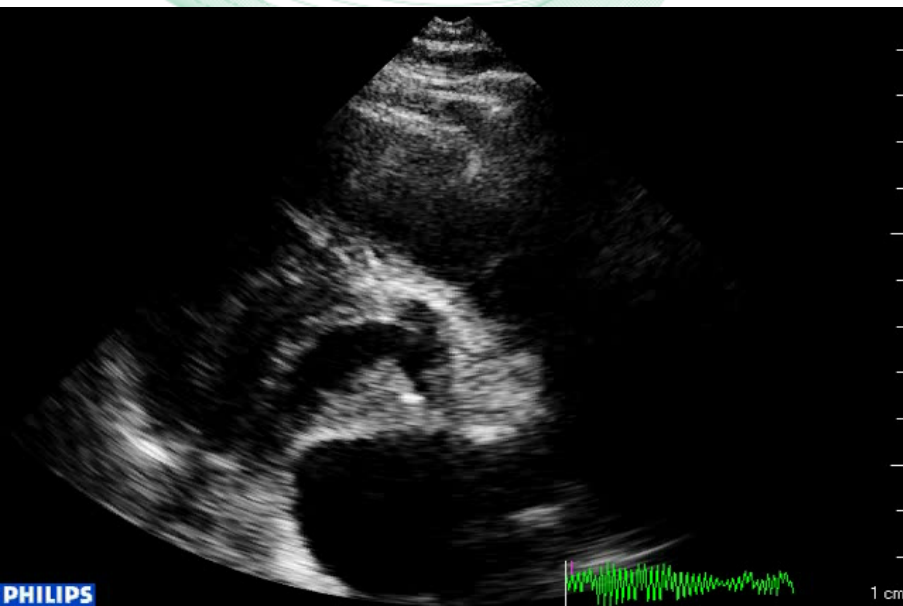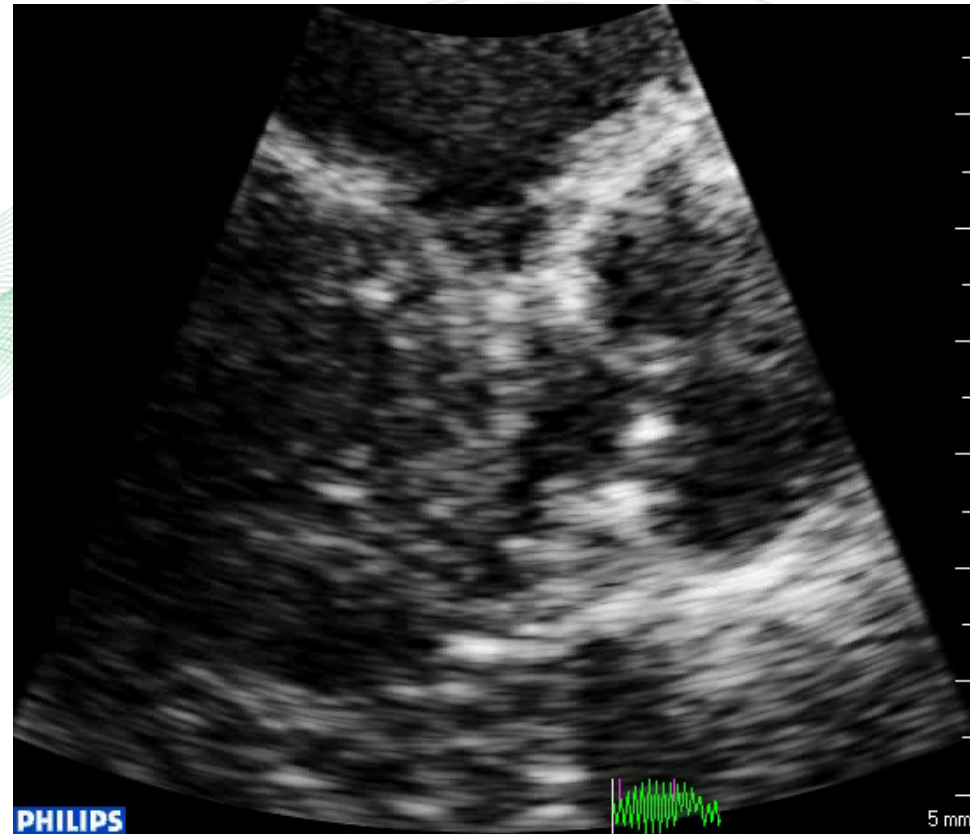
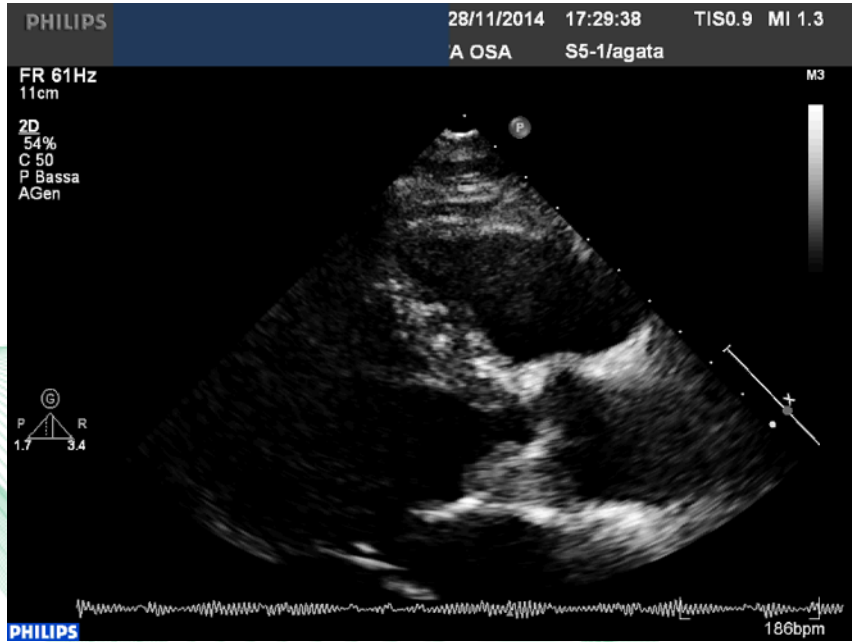
rsenior@cardiac-research.org

Evaluation of cardiac tumors with cardiovascular imaging aims to establish aetiology, identify complications of tumor and help define management strategy. 2D echocardiography remains the primary diagnostic modality. Additional use of newer echocardiographic techniques such as 3D, strain and contrast echocardiography better characterise tumor morphology, tissue characteristics and vascularity respectively. Cardiac MRI and computed tomography provide complementary information and are able to identify extra-cardiac infiltration and also provide further tissue characterisation. This review explores the non-invasive diagnostic approach to evaluation of cardiac tumors.


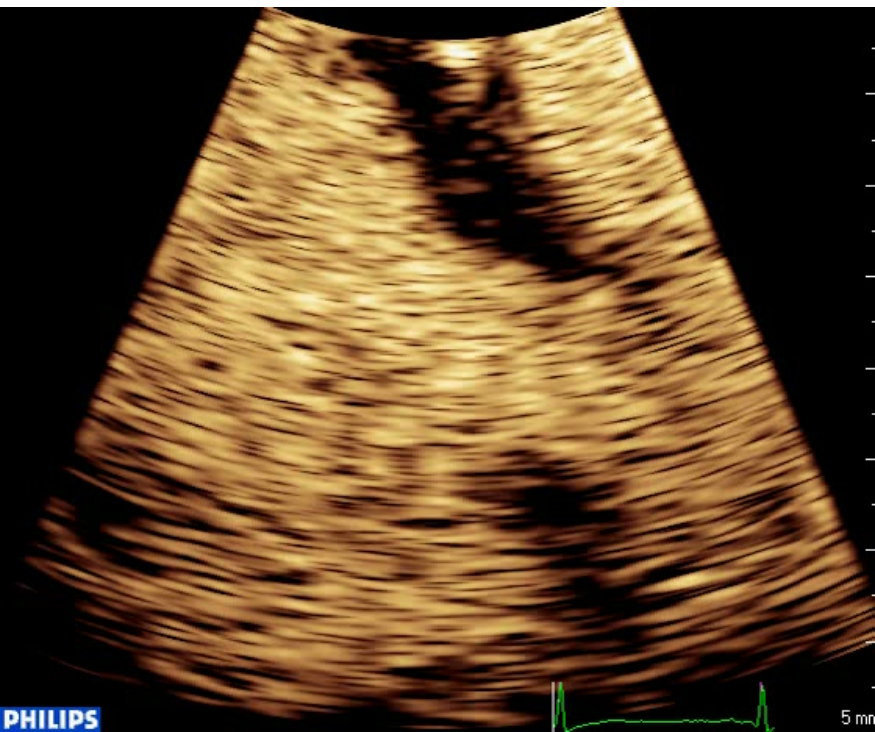
**Keywords:** cardiac magnetic resonance imaging • computed tomography • echocardiography • masses • tumors



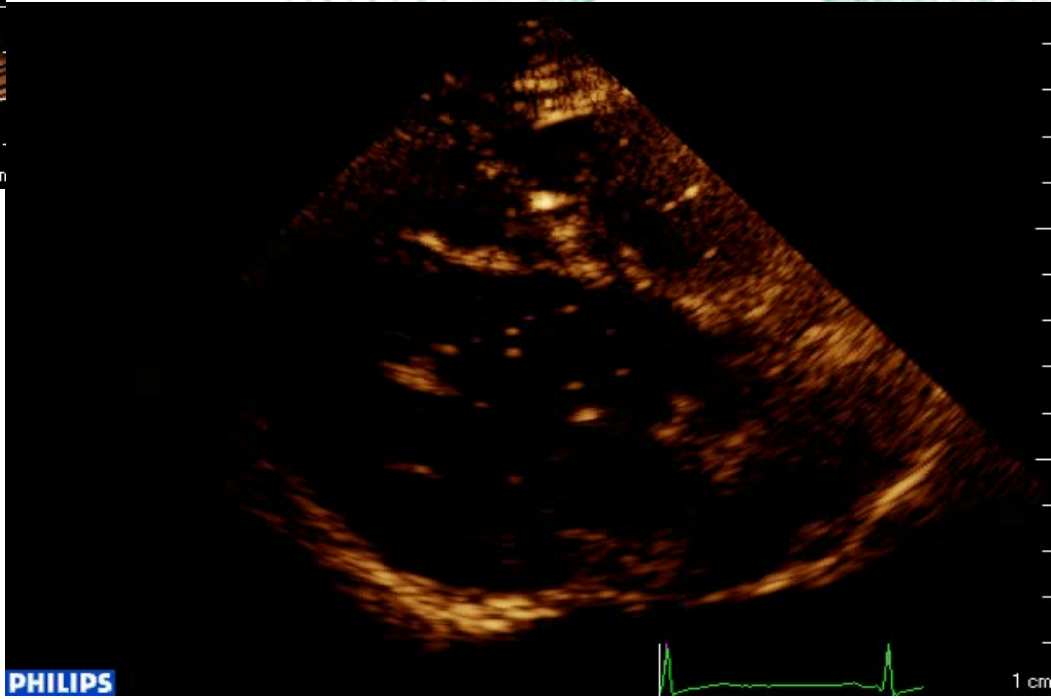
# Caso Clinico 4: M 40aa Ictus recente + soffio sisto diastolico aortico



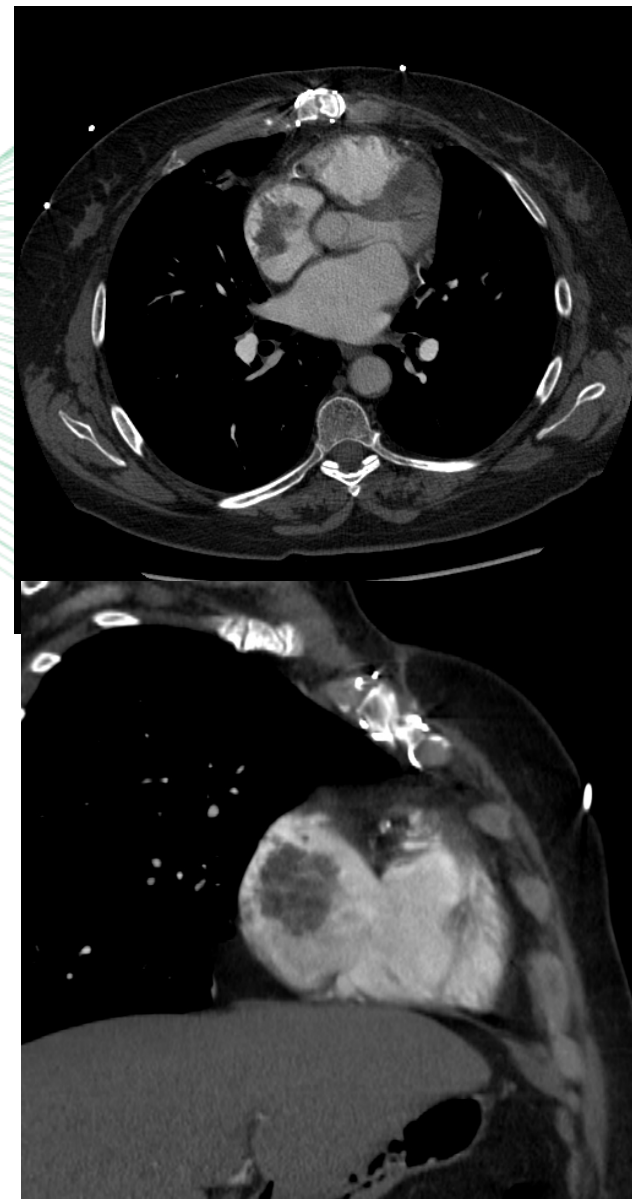
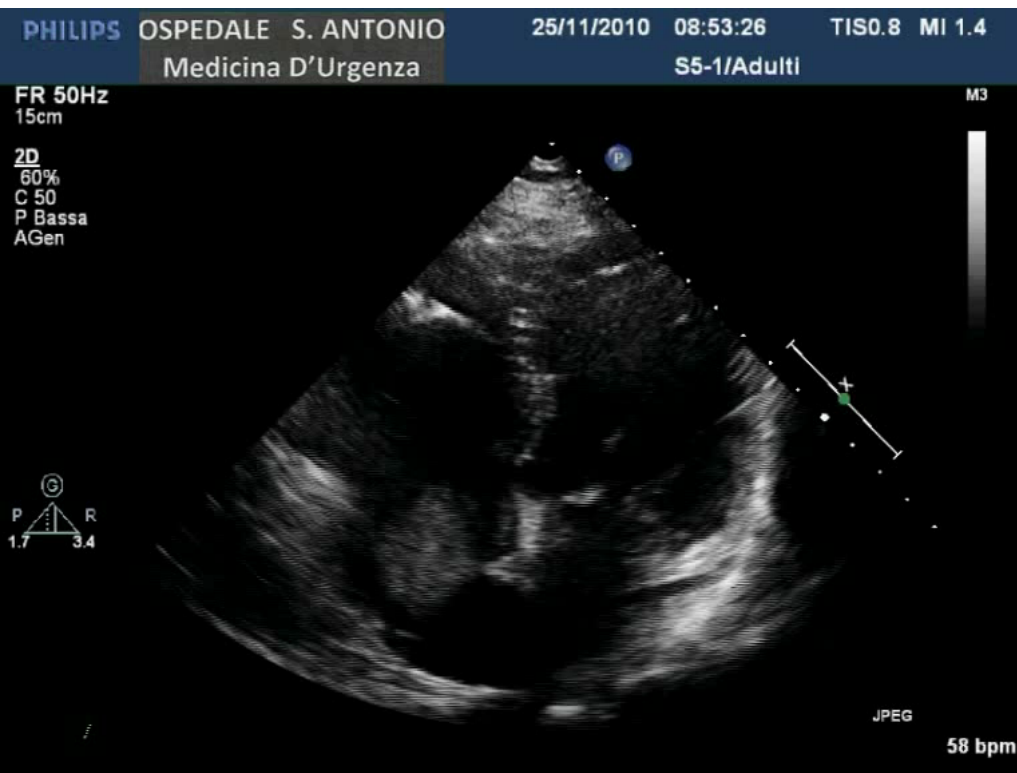
# 1) Contrast no enhanced: trombo



Very low MI : 0.1

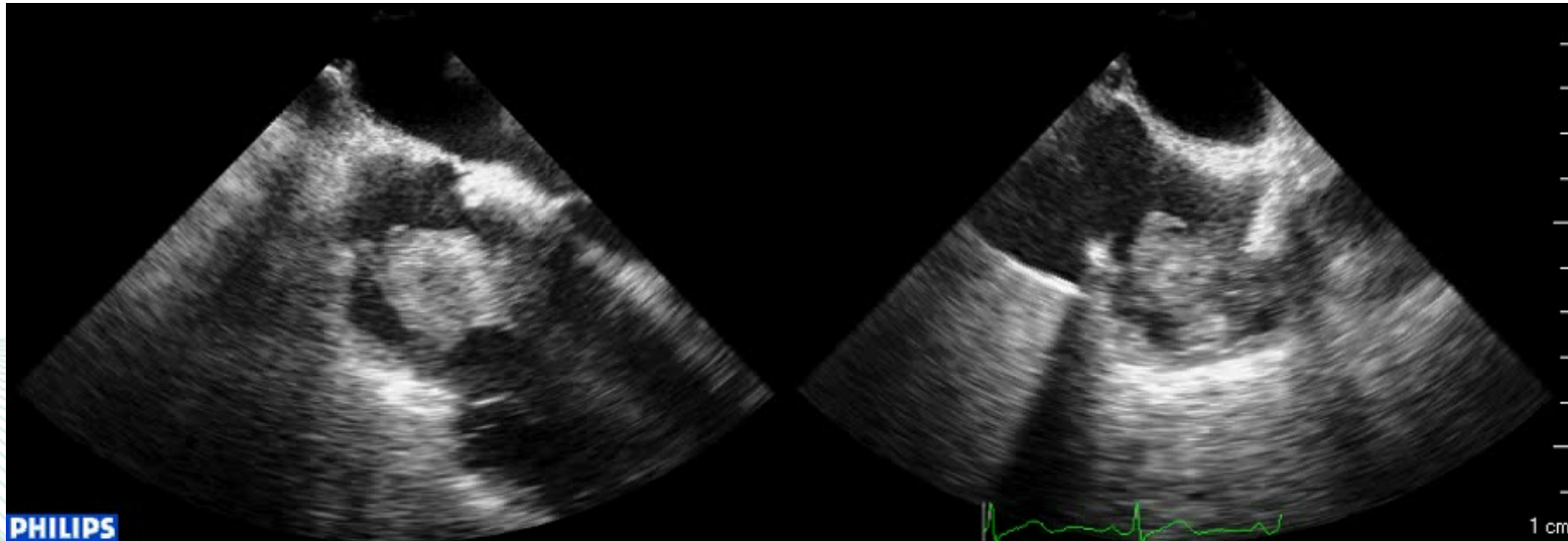


Caso 5 : F 60 aa, pregresso CABG (2007), TTE nel 2008 nella norma, sintomatica per dispnea.  
Angio TC Polmonare: "sospetto trombo AD, assenza di EP"





.....Il giorno successivo si eseguiva TEE



PHILIPS 11/25/2010 12:33:11 TIS0.2 MI 0.5  
X7-2t/Adultl

FR 13Hz  
11cm

Live 3D  
3D 27%  
3D 31dB  
Gen

0 110 180

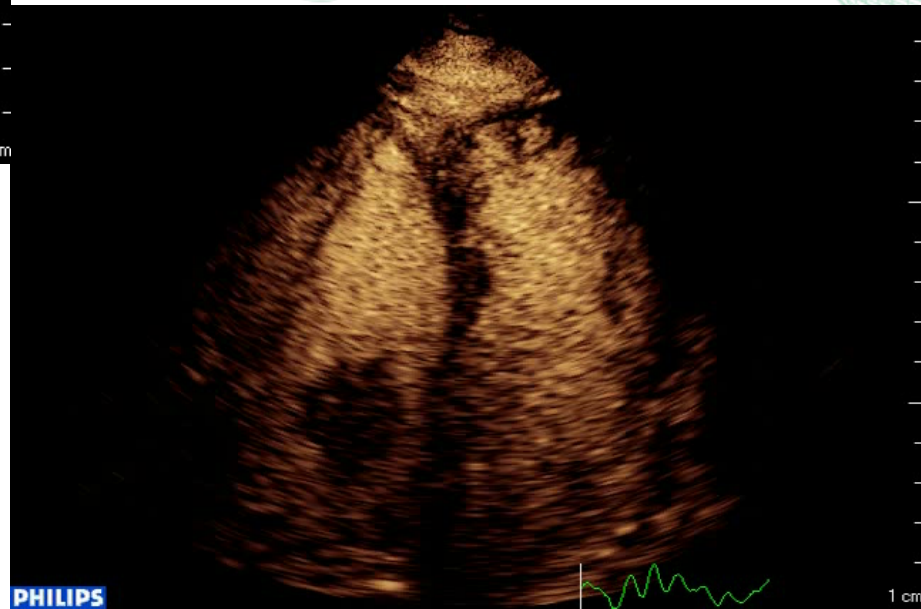
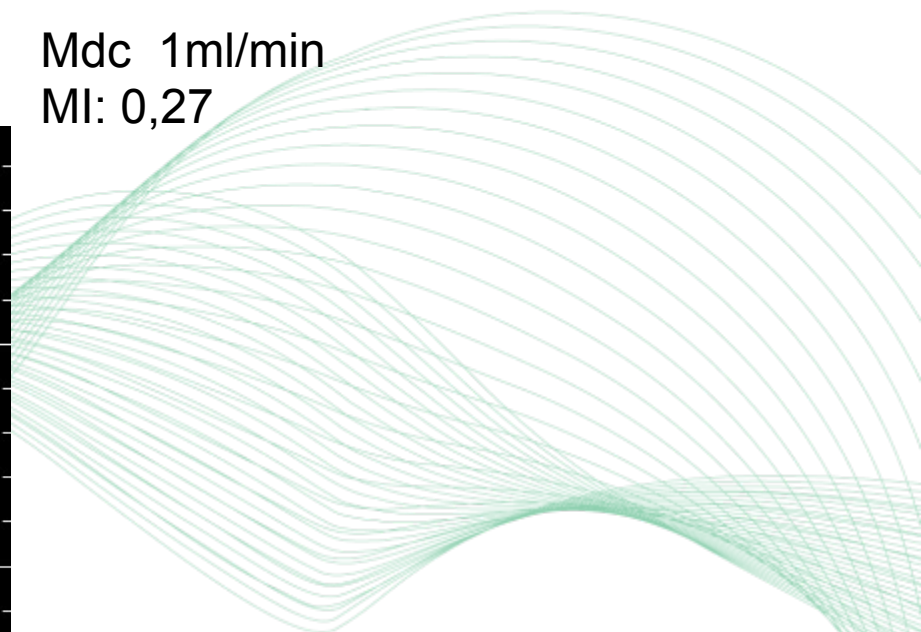
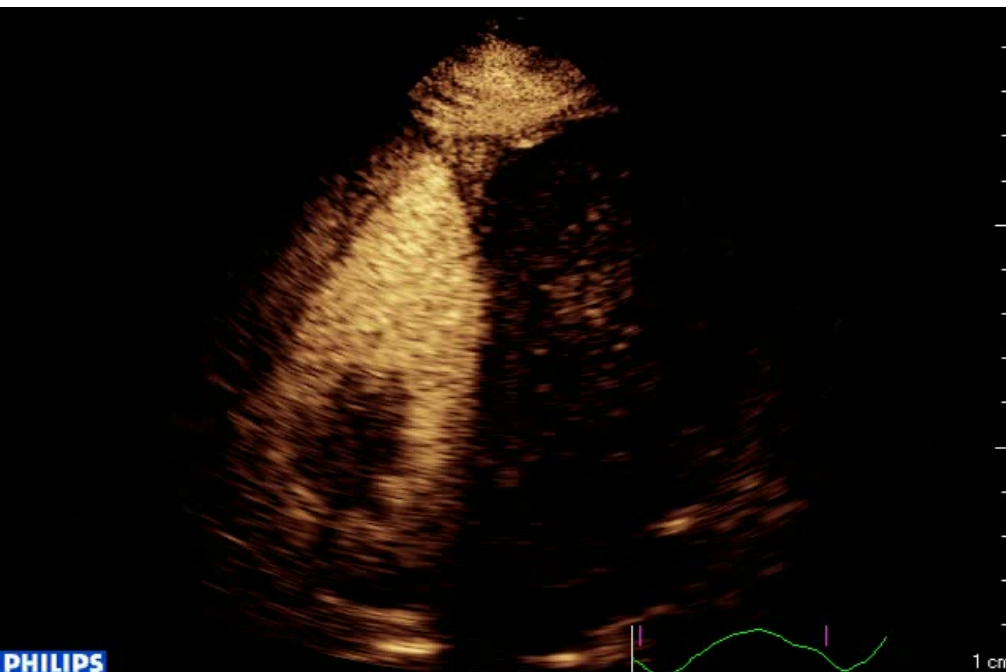
M4

JPEG 64 bpm

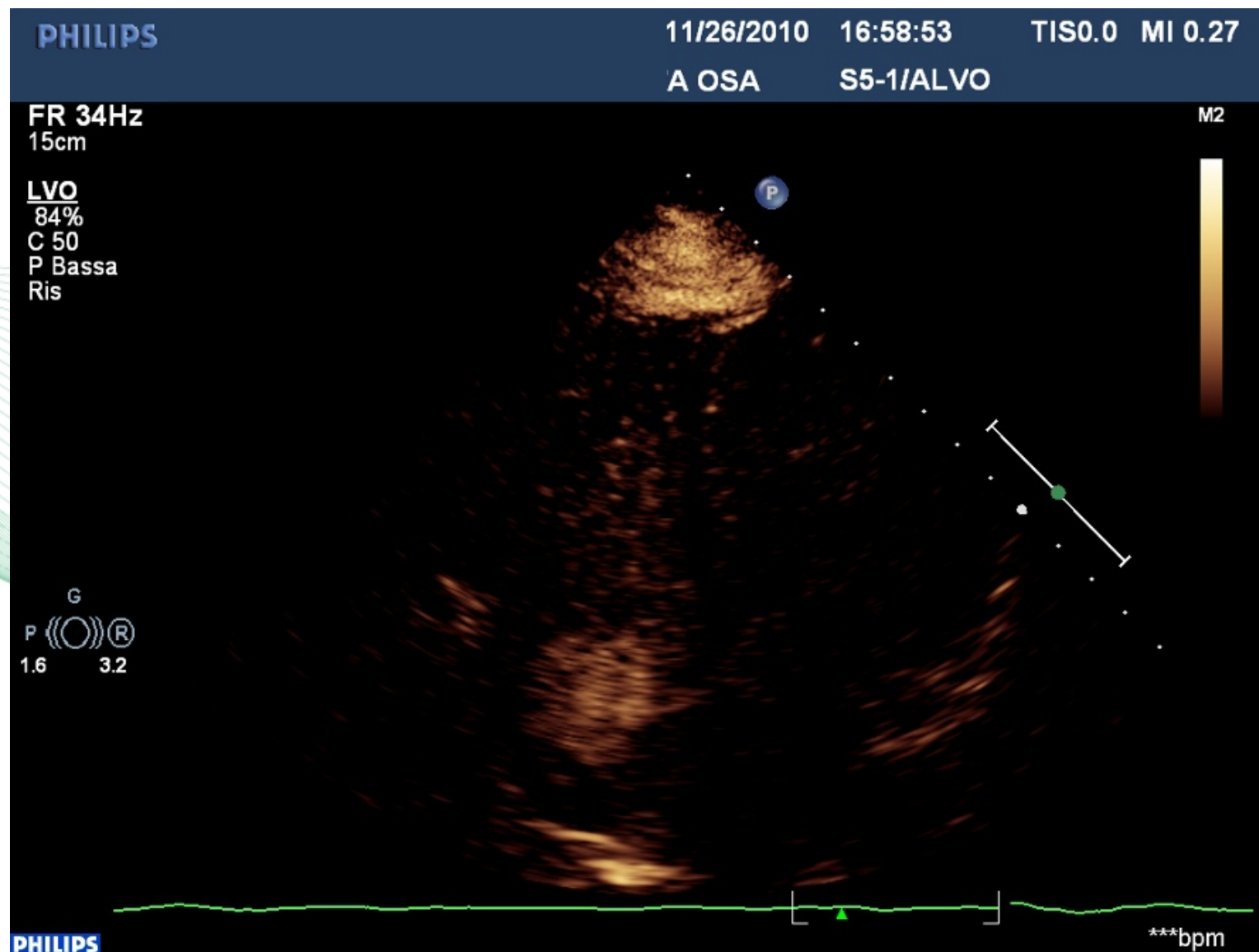
PHILIPS Temp. PAZ.: 37.0C  
Temp. TEE: 39.4C

# Ecocontrastografia

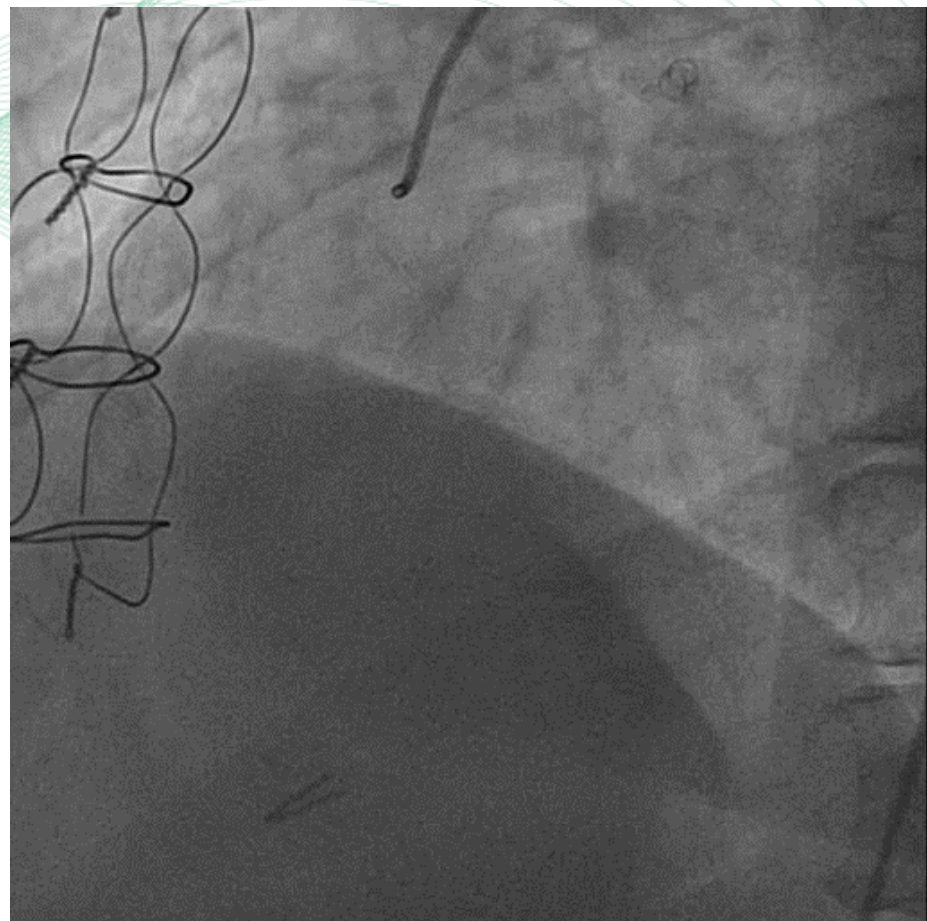
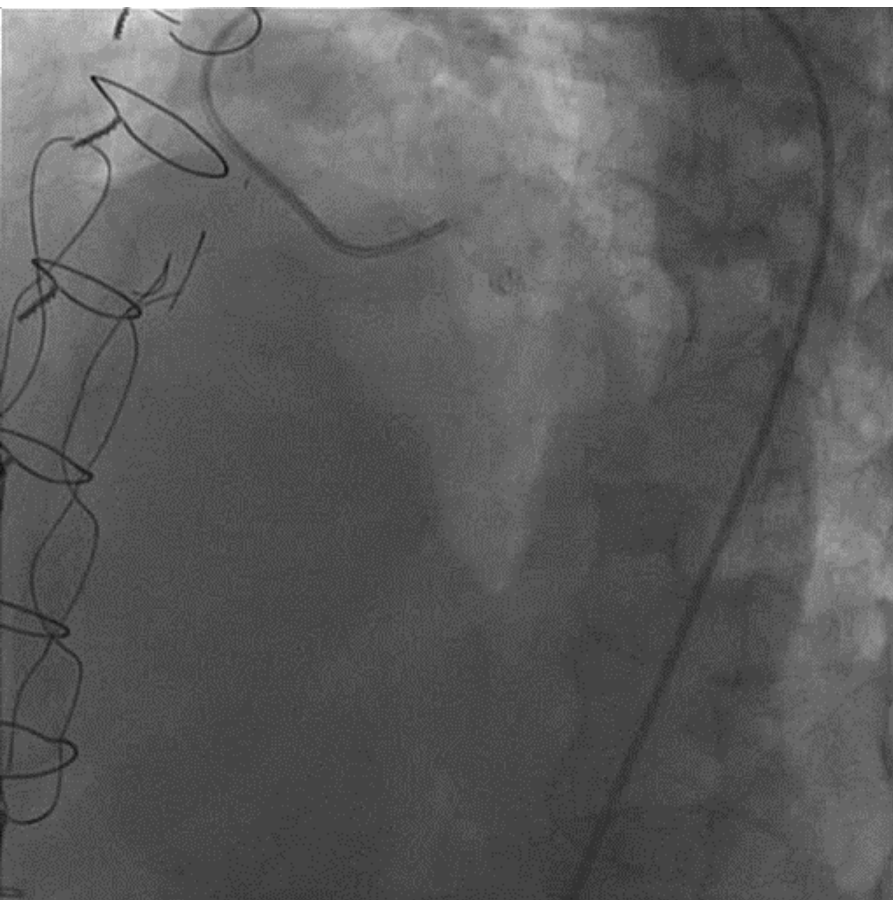
Mdc 1ml/min  
MI: 0,27



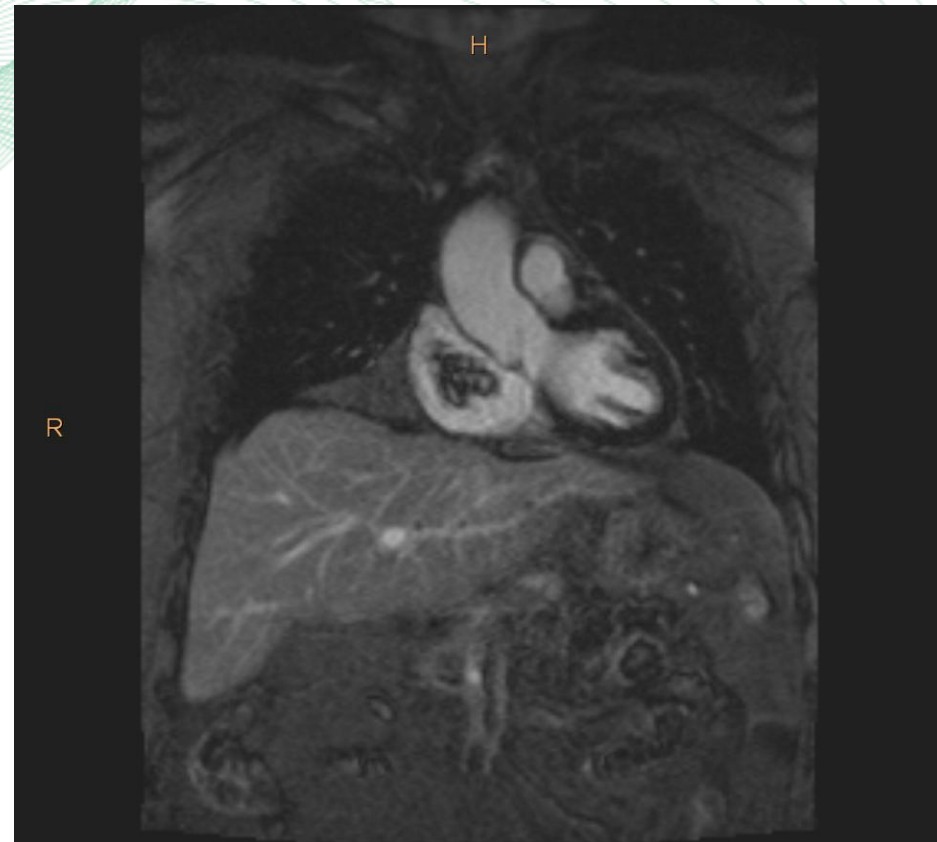
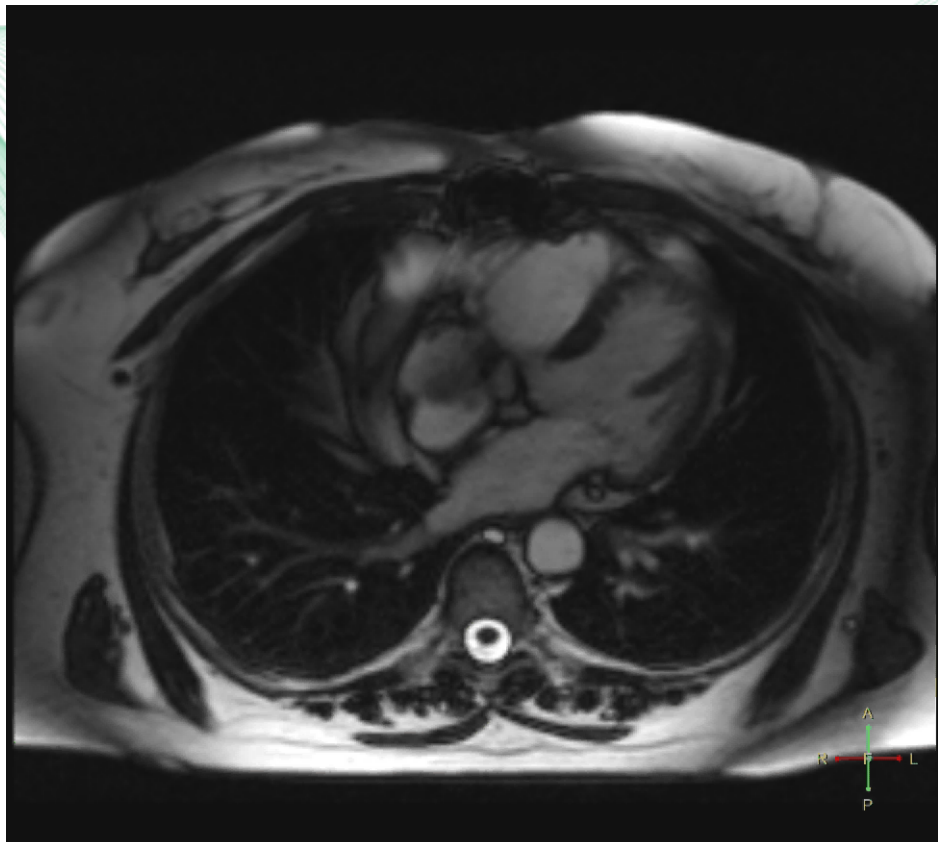
....dopo 3 min **Contrast enhanced: massa vascolarizzata (mixoma)**



CGF: assenza di evidente vascolarizzazione della massa



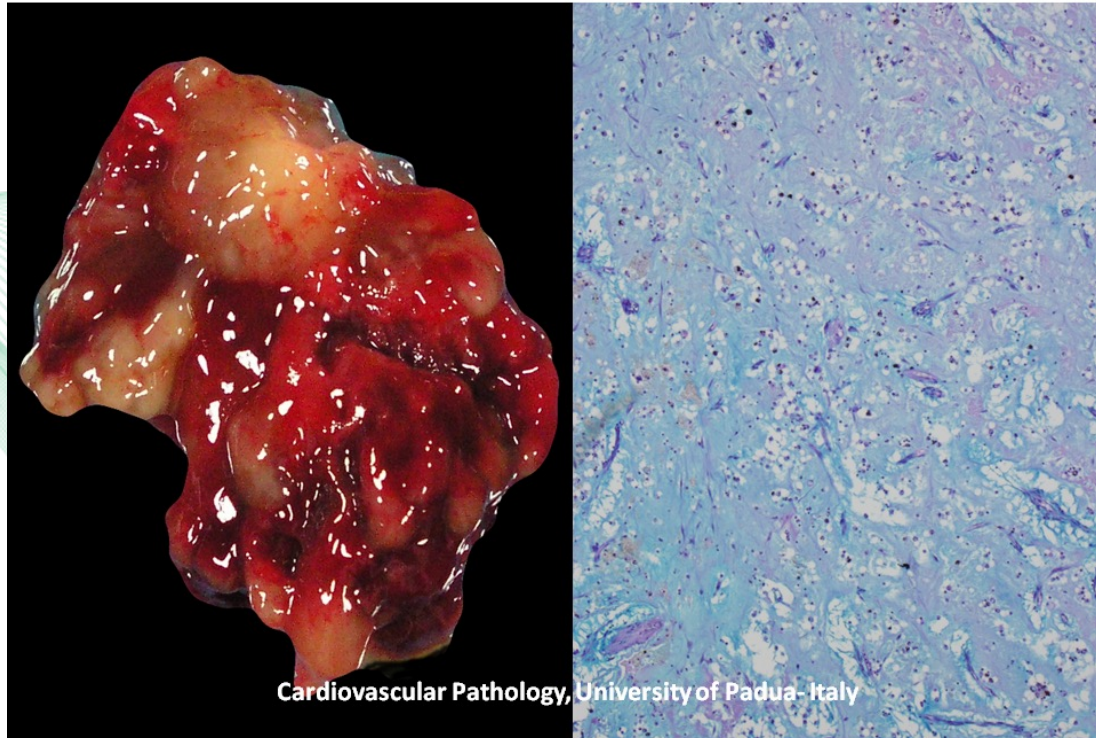
## RMN con gadolinio con la conferma di massa atriale destra vascolarizzata



La paziente si sottoponeva ad intervento cardiocirurgico dopo 2 gg

Reperto istologico compatibile con mixoma

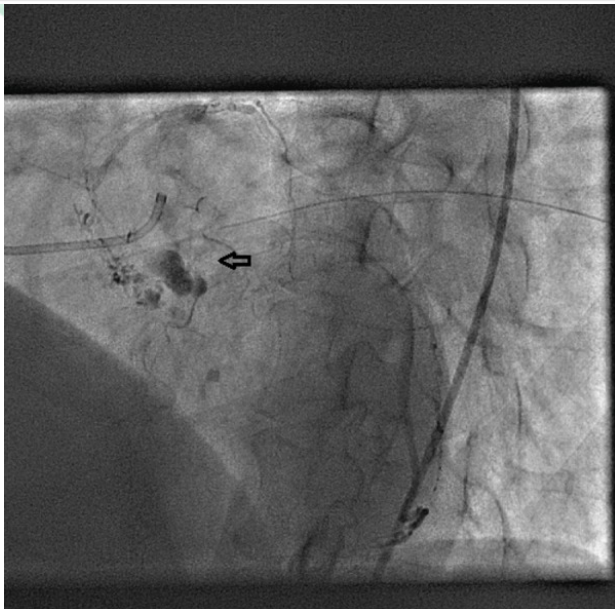
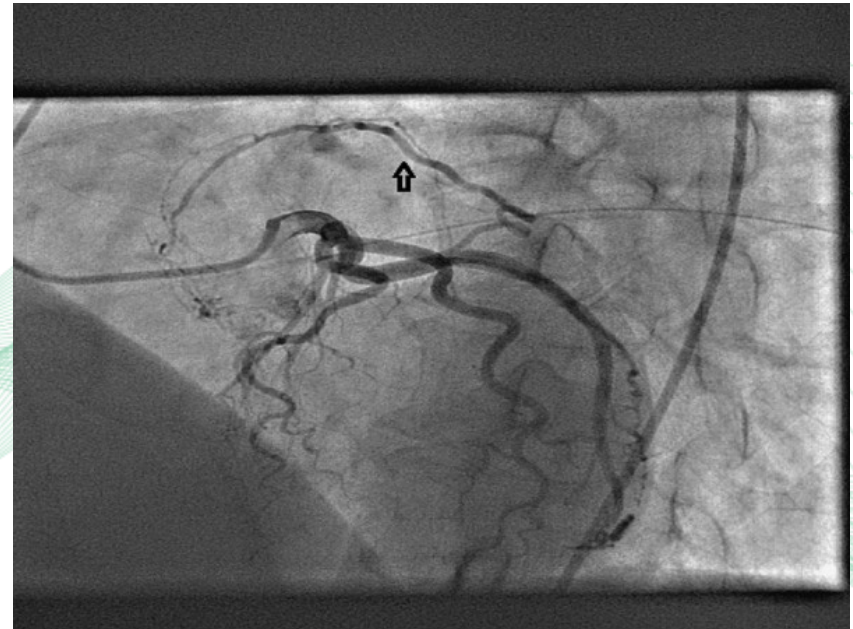
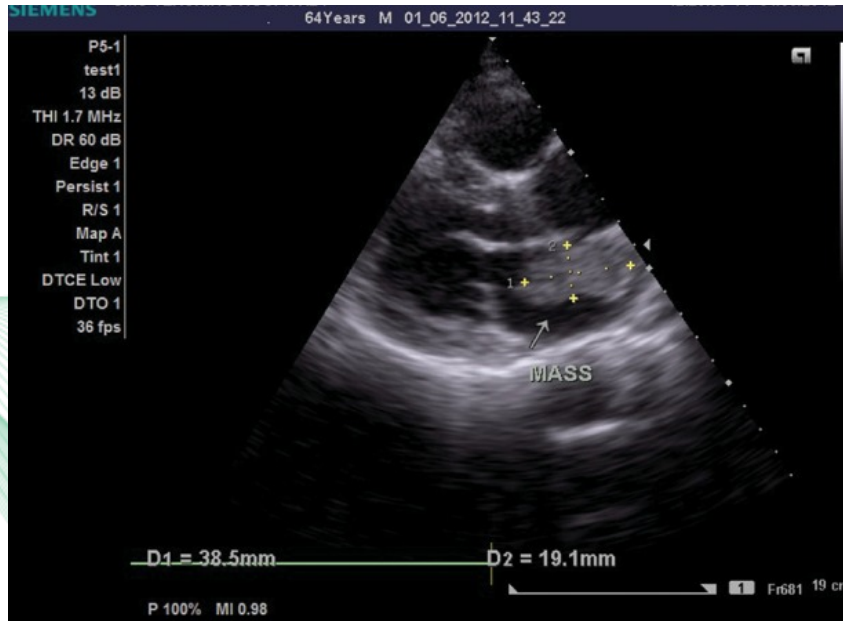
Escissa una massa di circa 4 x 3 cm plurilobata con aree trombotiche emorragiche ed aree di tessuto mixoide



**“Atrial Myxomas Grow Faster Than We Think”**

“Reports with documented growth rate are therefore very rare, and the actual growth rate remains a controversial issue. ...A **MEDLINE search** with the terms “cardiac myxoma and tumor growth” was performed. ***The calculated growth rate showed an average growth rate of 0.49 cm/month.*** These reports suggest that the growth rate of myxomas may be faster than is usually thought.”

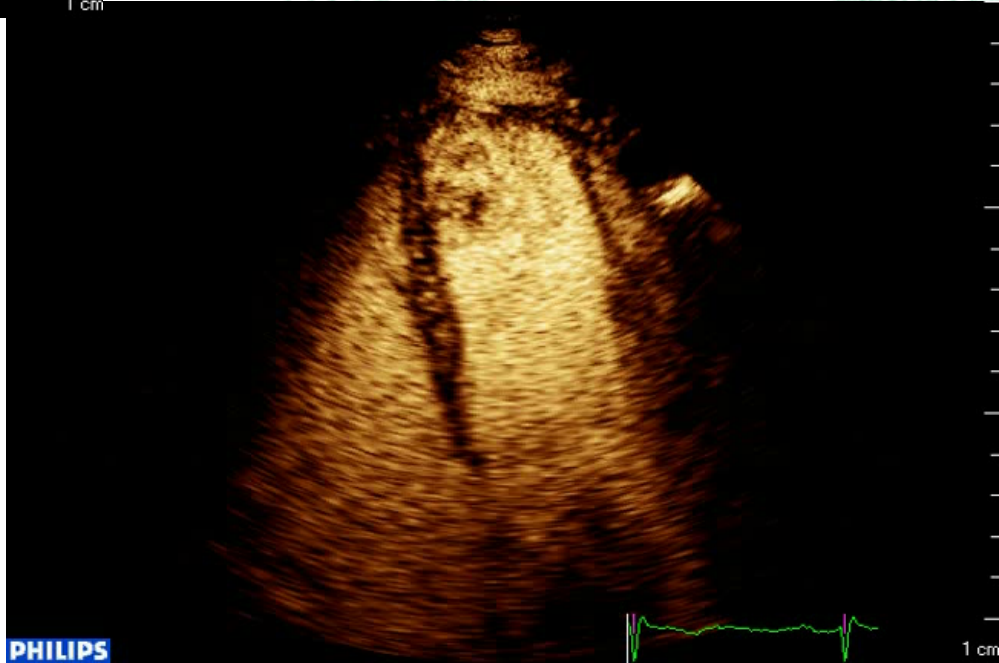
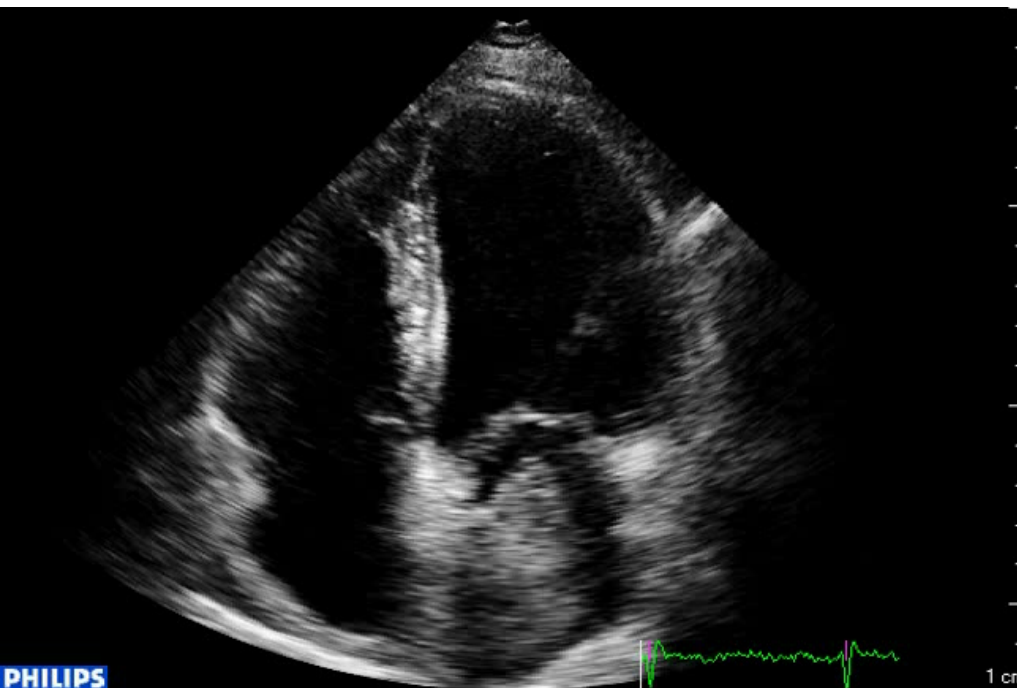
## Neovascularization in left atrial mixoma



**Left Atrial Mass (Arrow) Stained with Contrast Injected in the Left Coronary Artery System, Excellently Imaged Due to the Marked Contrast Enrichment in the Late Phase**

L. Dubey et al . Int Cardiovasc Res J. 2012 Dec; 6(4): 133–134.

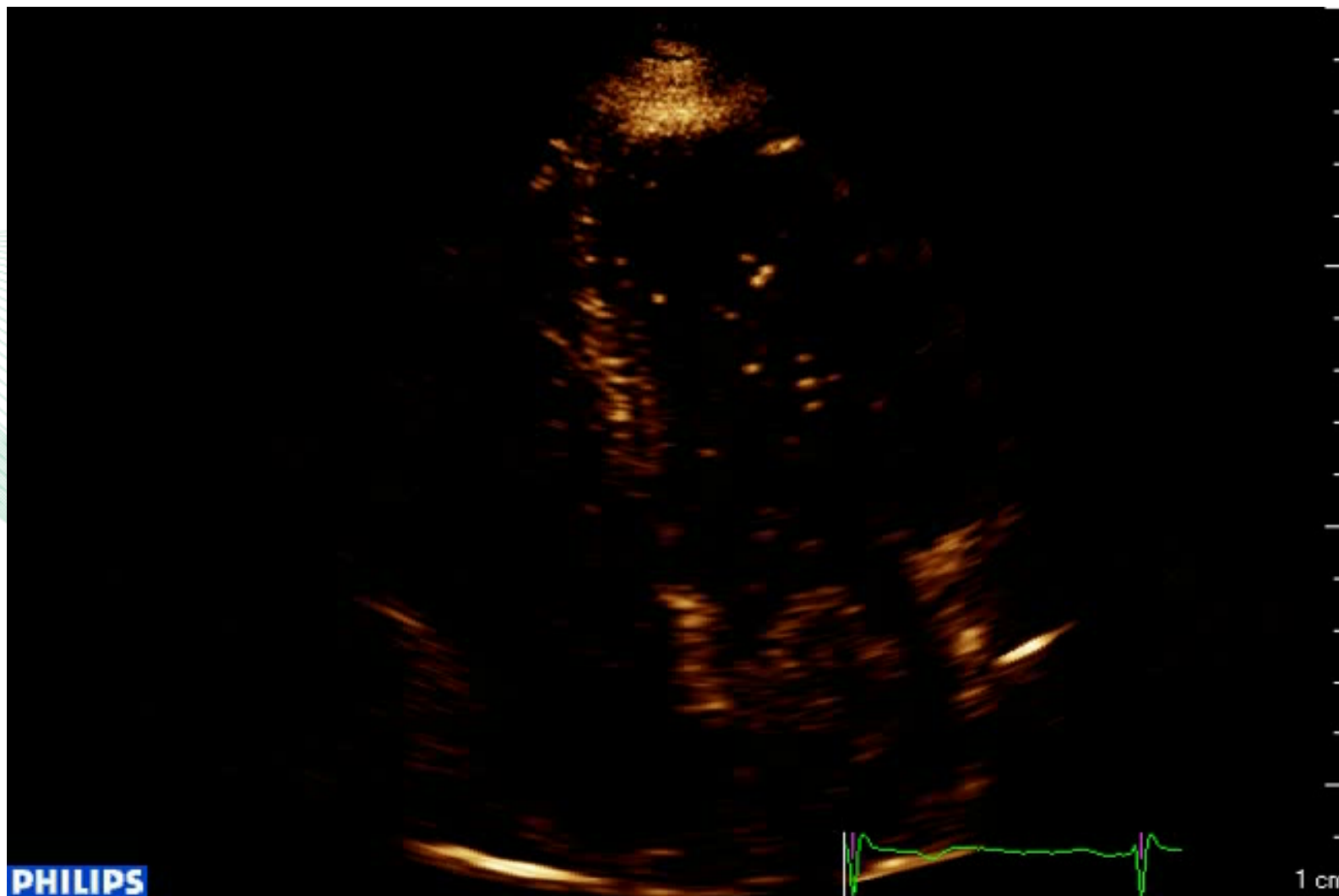
Caso 6: M 75aa recente ictus cerebrale



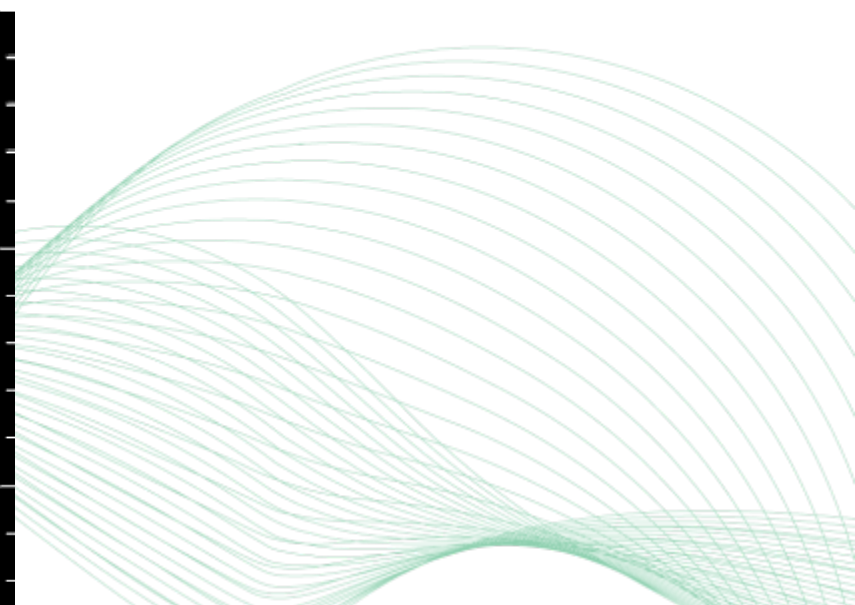
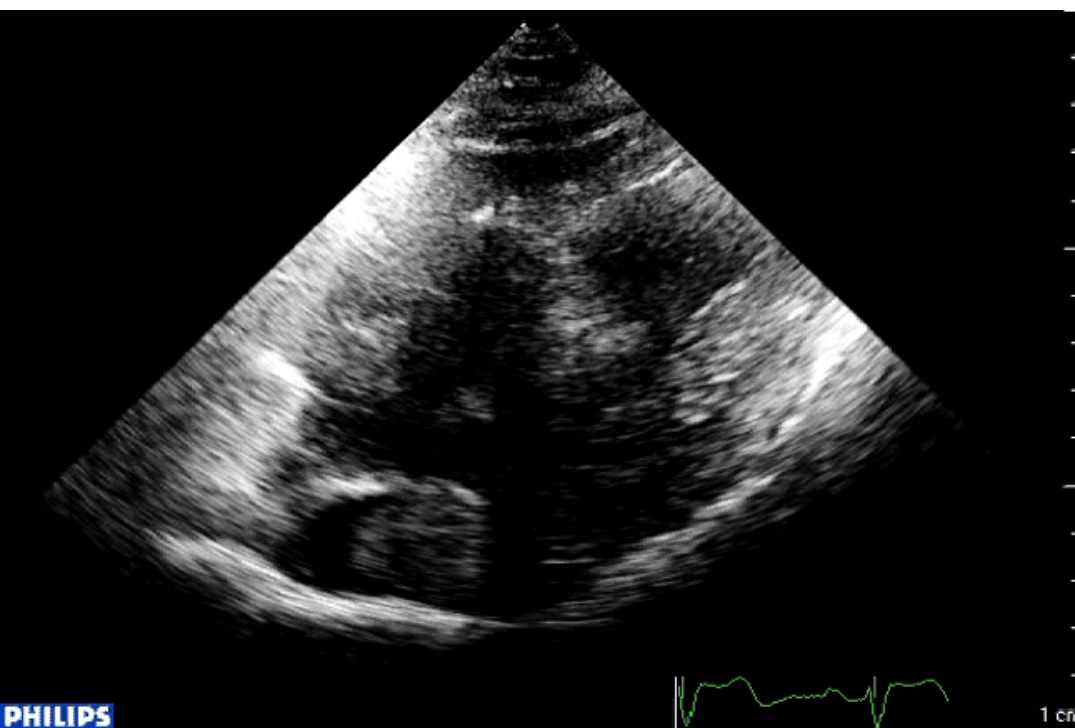


...late phase

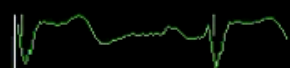**Contrast hypoenhanced: mixoma**



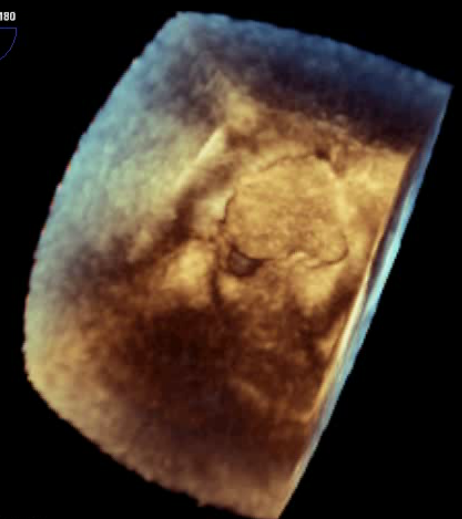# Caso 7: M 55 aa sintomatico per dolore toracico



PHILIPS 15/09/2011 11:32:06 TIS0.1 MI 0.7  
X7-2t/Adulti



5Hz  
1 cm  
Live 3D  
3D 47%  
3D 40dB  
Gen



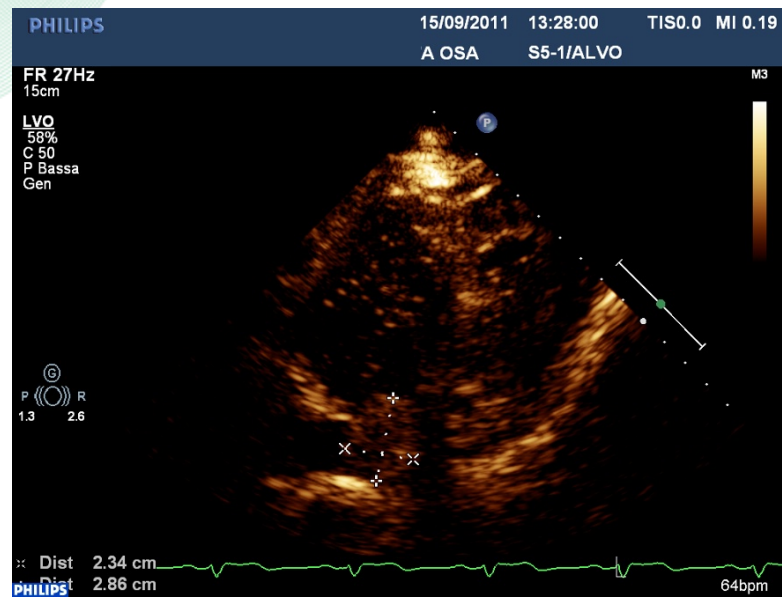
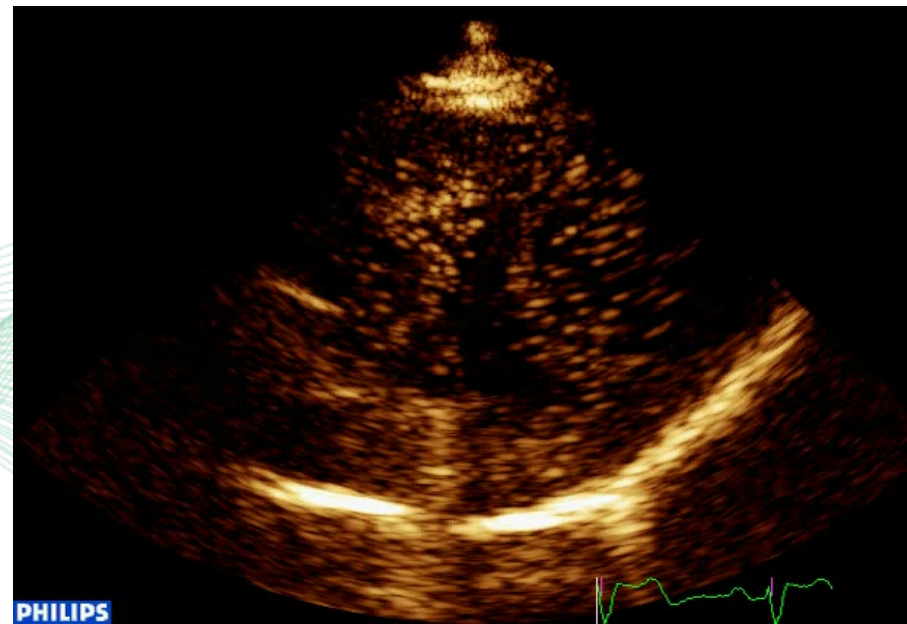
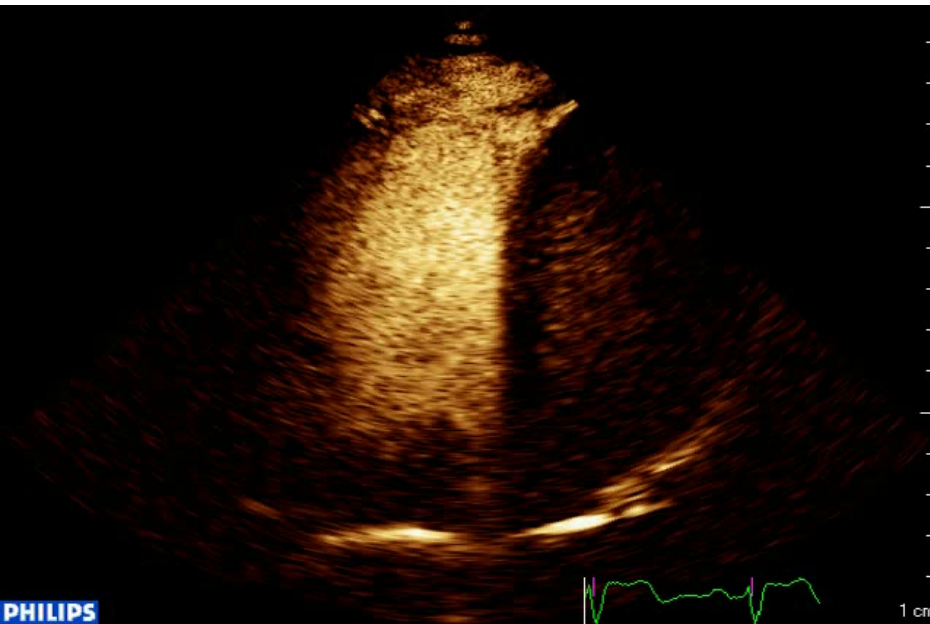
PHILIPS Temp. PAZ: 37.0C  
Temp. TEE: 38.5C

JPEG

78 bpm

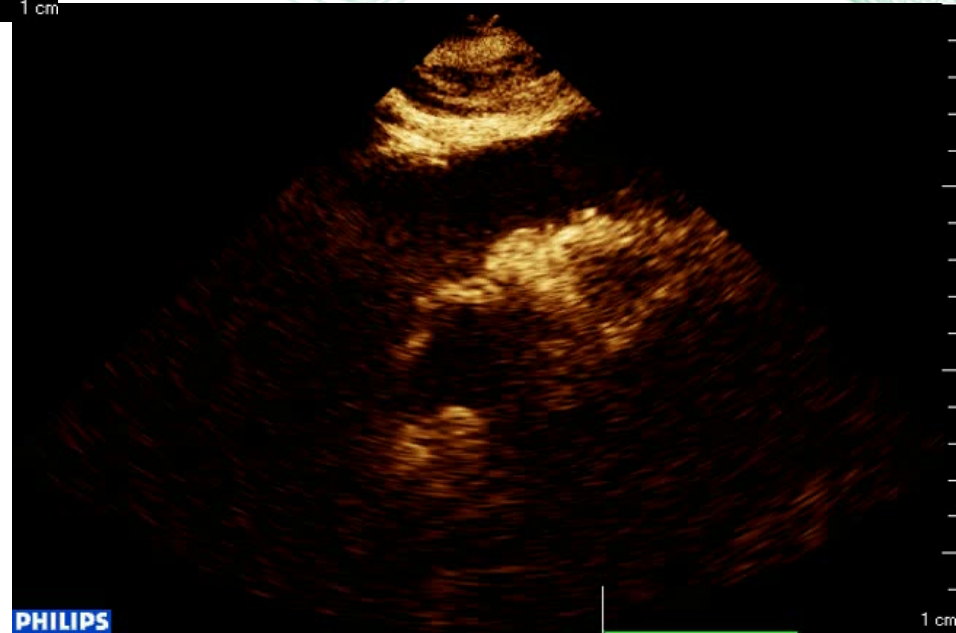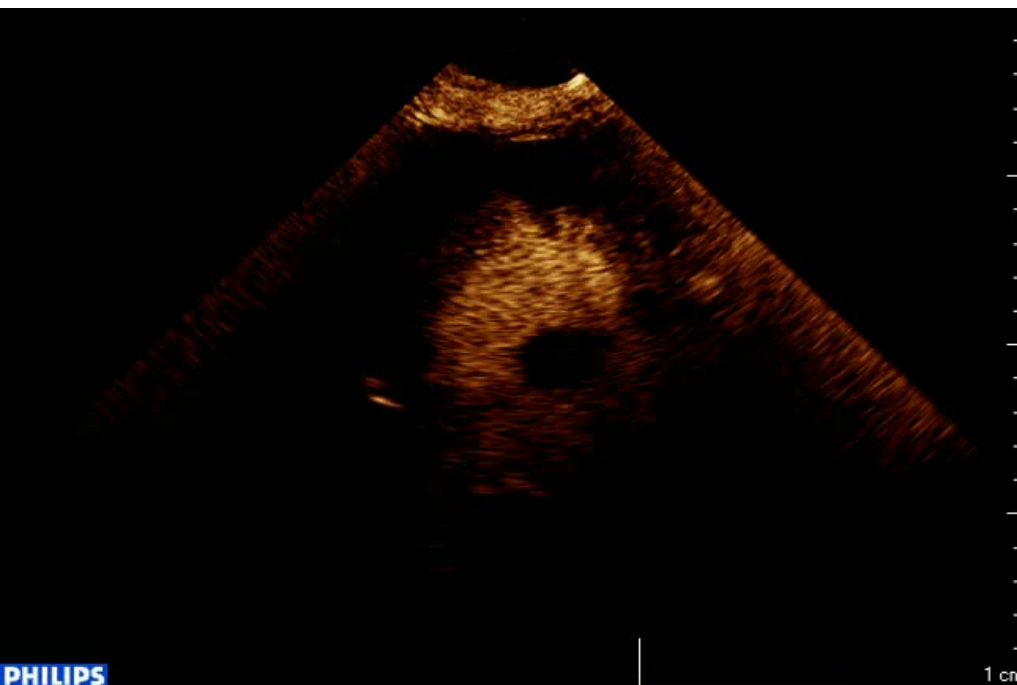
### 3) Contrast hyperhanced ( masse ipervascolarizzate): emangioma

CEUS MI: 0.19



Caso clinico 8: F 65 aa affetta da linfoma NH sintomatica per dispnea...

**3) Contrast hyperhanced ( masse ipervascolarizzate): metastasi LNH**



## Conclusioni

1. E' noto il valore aggiunto dell' ' ecocontrastografia nel rimodellamento ventricolare sia nei termini per l' opacificazione ventricolare che per la perfusione miocardica in termini predittivi e terapeutici
2. E' anche noto il valore dell' LVO ai fini di escludere la presenza di trombosi intraventricolare
3. Pochi dati ma incoraggianti avvalorano ecocontrastografia nell' identificazione della vascolarizzazione delle masse cardiache
4. La CEUS identifica la vascolarizzazione delle masse con setting low e very low MI , anche in fase tardiva
5. I dati ottenuti dalla CEUS vanno sicuramente correlati con i dati clinico-anamnestici e con le altre indagini strumentali (RMN, angiografia, TC ) per una completa definizione della caratterizzazione delle masse cardiache



The Journal of Sexual Medicine  
The Journal of Sexual Medicine

REPRODUCTIVE  
MEDICINE SECRETS  
HANLEY & BELTUS

CONGRESSO NAZIONALE S.I.U.  
TALE MASCHILE  
doctors

URETEROSCOPY

ISAAC ASIMOV  
ESTERFANDO  
L'ATTEFFALE L'ECOSMO

Inferilità maschile un testo illustrato  
Editors  
Indira Borini  
Filippo Maria Ubaldi

INFERITÀ  
Third Edition

Walsh  
Retik  
Stamey  
Vaughan  
CAN

STANDARD PRACTICE IN  
Sexual Med

Goldstein  
SURGERY

CAEUROPEI

Impara a conoscere  
I DINOSAURI